

REVIEW

Isolated nail lichen planus: An expert consensus on treatment of the classical form

Matilde Iorizzo, MD, PhD,^a Antonella Tosti, MD,^b Michela Starace, MD, PhD,^c Robert Baran, MD,^d
 C. Ralph Daniel III, MD,^{e,f} Nilton Di Chiacchio, MD, PhD,^g Sophie Goettmann, MD,^h
 Chander Grover, MD, DNB,ⁱ Eckart Haneke, MD, PhD,^j Shari R. Lipner, MD, PhD,^k Phoebe Rich, MD,^l
 Bertrand Richert, MD, PhD,^m Dimitris Rigopoulos, MD, PhD,ⁿ Adam I. Rubin, MD,^o Martin Zaiac, MD,^p and
 Bianca Maria Piraccini, MD, PhD^c

Bellinzona and Bern, Switzerland; Miami, Florida; Bologna, Italy; Cannes and Paris, France; Jackson, Mississippi; Birmingham, Alabama; São Paulo, Brazil; Delhi, India; New York, New York; Portland, Oregon; Brussels, Belgium; Athens, Greece; and Philadelphia, Pennsylvania

Lichen planus is a benign inflammatory disorder of unknown etiology that may affect the skin, mucosae, scalp, and nails. When the nails are affected, it may lead to permanent destruction with severe functional and psychosocial consequences. Therefore, prompt diagnosis and early treatment are essential, even in mild cases. There are currently no guidelines for the management of nail lichen planus and the published literature on treatment is limited. The aim of this review is to provide practical management recommendations for the classical form of nail lichen planus, especially when restricted to the nails. Topical treatment has poor short-term efficacy and may cause long-term side effects. Instead, intralesional and intramuscular triamcinolone acetonide should be considered first-line therapies. Oral retinoids are second-line choices, and immunosuppressive agents may also be considered. (J Am Acad Dermatol <https://doi.org/10.1016/j.jaad.2020.02.056>.)

Key words: acitretin; alitretinoin; consensus; guidelines; intralesional steroid injections; lichen planus; management; nail dystrophy; nail fissuring; nail lichen planus; nail ridging; retinoids; treatment; triamcinolone acetonide.

Lichen planus (LP) is a benign inflammatory disorder of unknown etiology that may affect the skin, mucosae, scalp, and nails.^{1,2} Nail involvement affects adults more than children.^{3,4} Fingernails are more commonly affected than toenails. Different clinical presentations have been recognized,^{5,6} but in this review we will discuss management of the classical variant, especially when restricted to the nail unit.

The longitudinal pattern of nail plate ridging and fissuring is quite characteristic of this variety of nail lichen planus (NLP). Onycholysis and nail bed hyperkeratosis may also be present. Dorsal pterygium, anonychia, and nail bed atrophy are, instead, less frequent.⁷ In most cases the diagnosis of NLP is clinical, but in questionable cases, obtaining a biopsy specimen is necessary, with the biopsy site selected according to the findings of the clinical examination.⁸

From private practice,^a Bellinzona; University of Miami, Miller School of Medicine^b and the Greater Miami Skin and Laser Center,^p Department of Dermatology, Herbert Wertheim College of Medicine, Florida International University, Miami; Department of Specialized, Experimental and Diagnostic Medicine,^c University of Bologna; University of Franche-Comté,^d Nail Disease Center, Cannes; University of Mississippi Medical Center,^e Jackson; University of Alabama,^f Birmingham; Department of Dermatology,^g Hospital do Servidor Público Municipal de São Paulo; private practice,^h Paris; Department of Dermatology and STD,ⁱ University College of Medical Sciences and GTB Hospital, Delhi; Department of Dermatology,^j Inselspital, Bern University Hospital, Bern; Department of Dermatology,^k Weill Cornell Medicine, New York; Oregon Health and Science University,^l Portland; Saint Pierre - Brugmann and Queen

Fabiola Children's University Hospitals,^m Université Libre de Bruxelles, Brussels; University Hospital of Venereal and Skin Diseases "A. Sygros,"ⁿ Athens; and the Department of Dermatology,^o Hospital of the University of Pennsylvania, Children's Hospital of Philadelphia, Perelman School of Medicine at the University of Pennsylvania, Philadelphia.

Funding sources: None.

Conflicts of interest: None disclosed.

Accepted for publication February 19, 2020.

Reprint requests: Matilde Iorizzo, MD, PhD, Viale Stazione 16 – 6500 Bellinzona, Switzerland. E-mail: matildeiorizzo@gmail.com.

Published online April 17, 2020.

0190-9622/\$36.00

© 2020 by the American Academy of Dermatology, Inc.

<https://doi.org/10.1016/j.jaad.2020.02.056>

Nail involvement in LP may be severe and can rapidly worsen, with irreversible scarring as a potential outcome. This causes significant discomfort to patients, affecting their quality of life. Therapeutic medications with proven efficacy are limited, and treatment is notoriously challenging, with high rates of failures, relapses, and recurrences. Improvement can be difficult to achieve if NLP is not properly and promptly treated.⁹

No guidelines exist for the treatment of NLP, and there is no medication with a specific indication for its treatment. Moreover, no validated scoring system exists to objectively assess the efficacy of prescribed medications. Treatment of the nail unit in general is notoriously challenging, because the delivery of topical drugs is difficult, mildly effective, and time-consuming, and clinicians are often reluctant to prescribe systemic treatments when the disease is localized only to the nails, thereby limiting potential therapeutic options.

MATERIALS AND METHODS

A literature search in the PubMed database was performed and a total of 21 papers were collected¹⁰⁻³⁰ (Supplemental Table I available via Mendeley at <https://doi.org/10.17632/fg2yfcs5kr.1>). Because of the limited published literature, we evaluated papers with cases of isolated NLP but also papers with LP affecting the nails and other body areas. However, because the purpose of this article was to review the efficacy of treatment, we believe that it should be evaluated independently if it was the more appropriate option to choose.

All authors of this review were then invited to participate in a survey to achieve the following goals.

Define the severity of clinical presentation. NLP severity has been defined as either mild, moderate, or severe. Mild NLP features: nail thinning, longitudinal ridging, distal splitting of <3 mm in length, onycholysis <25%, and no nail bed hyperkeratosis (Fig 1, A). Moderate NLP features: partial fissuring, longitudinal grooves, distal splitting of 3 to 5 mm in length, onycholysis between 25% and 50%, mottled erythema of the lunula, and subungual hyperkeratosis (Fig 1, B). Severe NLP features: complete fissuring, deep grooves, splitting of >5 mm in length, onycholysis >50%, and diffuse erythema of the lunula (Fig 1, C). Pterygium and anonychia belong to this last stage, but because they do not

respond to any treatment, they will not be discussed. A numeric score has not been created because in NLP the dystrophy is too diffuse and cannot be assessed in quadrants as in nail psoriasis.

Define when systemic treatment is preferred or indicated. “Few-nail disease” should be defined as a disease affecting ≤ 3 nails. However,

we do not impose the threshold of 3 nails for the initiation of a systemic treatment, but we indicate it as a suggestion. Patient quality of life is an important factor to take into account when prescribing a treatment because dystrophy involving the first 3 digits might have significant functional consequences even if the severity of the disease is mild, justifying systemic treatments.

Define the number of months necessary to evaluate the first results of treatment and the number of months over which a treatment is judged unsuccessful. There are no data on nail growth in NLP. Normal nail growth is 2 to 3 mm per month for fingernails and 1 to 2 mm per month for toenails³¹; a minimum of 3 to 6 months is necessary to evaluate the results of a given treatment.

Define the percentage of success of a treatment. No improvement or worsening is a disease reduction of 0%; minimal improvement is a disease reduction of $\leq 25\%$; mild improvement is a disease reduction of 26% to 50%; moderate improvement is a disease reduction of 51% to 75%; great improvement is a disease reduction of 76% to 99%; and clinical cure is a disease reduction of 100%.

RESULTS

After reviewing the published literature,¹⁰⁻³⁰ it is clear that treatment of NLP is challenging. Prospective studies with long-term follow-up have never been performed and evidence-based studies are not feasible because the pathogenesis of NLP and molecular targets for drug development are unknown. Most of the reported papers are single case reports or expert opinions where detailed data on disease localization and severity are lacking. This provides an incorrect evaluation of treatment efficacy and indications. Not all patients, and not even all affected nails, responded to the given therapy; not all patients responded in the same way and the first prescribed successful treatment was sometimes not effective in case of recurrences. It was impossible to

CAPSULE SUMMARY

- Nail lichen planus may cause significant discomfort and permanent nail destruction, so prompt treatment is essential.
- Intralesional triamcinolone acetonide is the first-line treatment, but systemic corticosteroids, retinoids, and immunosuppressive agents may also be considered.

Abbreviations used:

LP: lichen planus
NLP: nail lichen planus

predict which patients would respond to treatment and which patients would not. In general, because of a faster growth rate and reduced thickness, fingernails responded better and quicker than toenails; however, the thumb responded less and more slowly.

According to the authors' experience, however, effective treatment options exist and include intralesional and systemic treatments (Fig 2). Topical treatment is not recommended because of limited drug penetration and potential side effects related to long-term application.³² Environmental exposures that may worsen the disease and delay treatment response should be limited or avoided.

DISCUSSION

According to the published literature and to the authors' experience, early treatment is always

recommended for NLP and the wait and see approach is generally not advisable because of the dystrophic nature of the disease and its unpredictable course.

It is important to suppress inflammation to treat NLP,^{33,34} and the first-line therapy should always be triamcinolone acetonide. The intralesional route of administration is considered an optimal targeted therapy because the drug is delivered to the site of inflammation—namely the nail matrix or nail bed—with numerous advantages if properly performed.

When the nail matrix is affected, injections are quite tolerable for patients, even for older children (at least >14 years of age). Ethyl chloride spray, “talkesthesia,” and the concomitant use of vibrating devices can be used instead of digital block anesthesia. Even 20 nails can be treated in 1 office visit in a few minutes. Injections in the nail bed are instead too painful without a digital block anesthesia.

While adverse events³⁵⁻³⁷ including atrophy are possible, there is strong consensus that they are minimal or even nonexistent when this technique is used with appropriate training.³⁸ Hematomas and

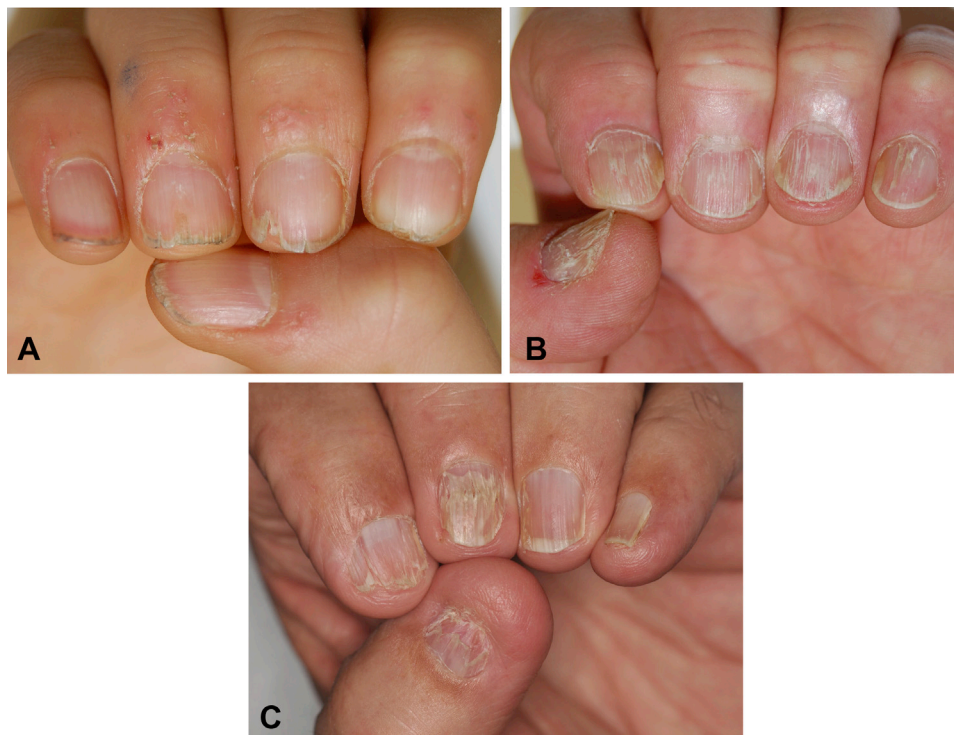

Fig 1. **A**, Mild nail lichen planus (NLP). Note the longitudinal ridging and splitting limited to the distal portion of the plate. Onycholysis is mild and nail bed hyperkeratosis is absent. **B**, Moderate NLP, featuring partial fissuring, longitudinal grooves, and distal splitting between 3 and 5 mm in length. Mottled erythema of the lunula can be roughly observed in the second fingernail. Onycholysis is more marked and nail bed hyperkeratosis can be observed in the thumb. **C**, Severe NLP, featuring complete fissuring and splitting >5 mm in length, onycholysis >50%, and diffuse erythema of the lunula.

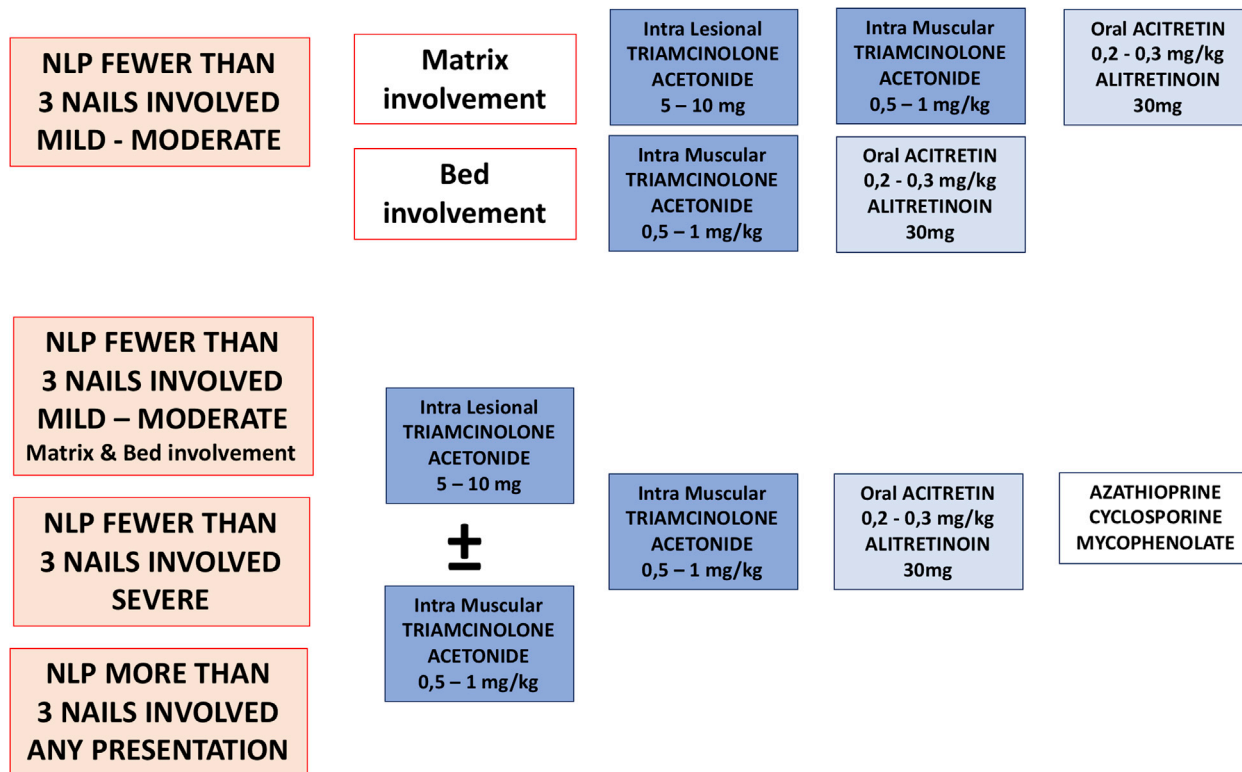


Fig 2. Clinical treatment algorithm according to the number of nails involved, disease severity, and inflammation location. Different shades of blue indicate the first to the third option selected according to authors' experience (not all treatments are approved by the regulatory authorities of all countries).

transient numbness of the distal digit are, instead, more frequent.

As with nail psoriasis,³⁹ there is not enough evidence regarding the optimal dosage, dilution, number and frequency of injections, and maximum duration of treatment.

According to the authors, triamcinolone acetate should be injected in a concentration of 2.5, 5, or 10 mg/mL according to disease severity. If lower-concentration vials are not commercially available, dilutions of 10 mg can be made with 1% lidocaine without epinephrine or sodium chloride. A volume of 0.1 mL per nail plate quadrant is enough and the solution should be slowly injected with a 30-g needle. The needle should be inserted until a loss of resistance and then the liquid injected until blanching of the area is observed.³⁸ An insulin syringe with a built-in needle or a Luer lock syringe are best for injections under pressure, a frequent issue when injecting within the nail unit. Different injection techniques are shown in Fig 3.^{40,41} Needleless injecting instruments (Port-O-Jet or Dermojet [Robbins Instruments, Chatham, NJ]) are not supported by the authors because of the potential risk of splash back of blood and the scarce

manageability of the existing instruments on a small and convex structure like the nail unit.

Injections should be repeated every 4 to 5 weeks, for a minimum of 4 to 6 months to appreciate results. If improvements are seen, it is appropriate to continue until there is marked or complete improvement and then to taper for a few months. Tapering is best performed by extending the period between injections (once every 6 to 8 weeks). If no clinical response is achieved after 6 sessions, another treatment modality should be evaluated, and tapering is not necessary.

Intramuscular triamcinolone should be considered as an adjunct to intralesional administration in case of severe disease, especially if >3 nails are affected, in any presentation. Intramuscular triamcinolone is also recommended if intralesional injections are not feasible because the patient is affected by nail bed LP, the physician lack of expertise, or if the patient refuses them. It should be done even if there is one or few nails affected as stated earlier.

A dose of 0.5 to 1 mg/kg every month for at least 3 to 6 months is suitable for both children and adults, with dosages of 1 mg/kg/month advised during the

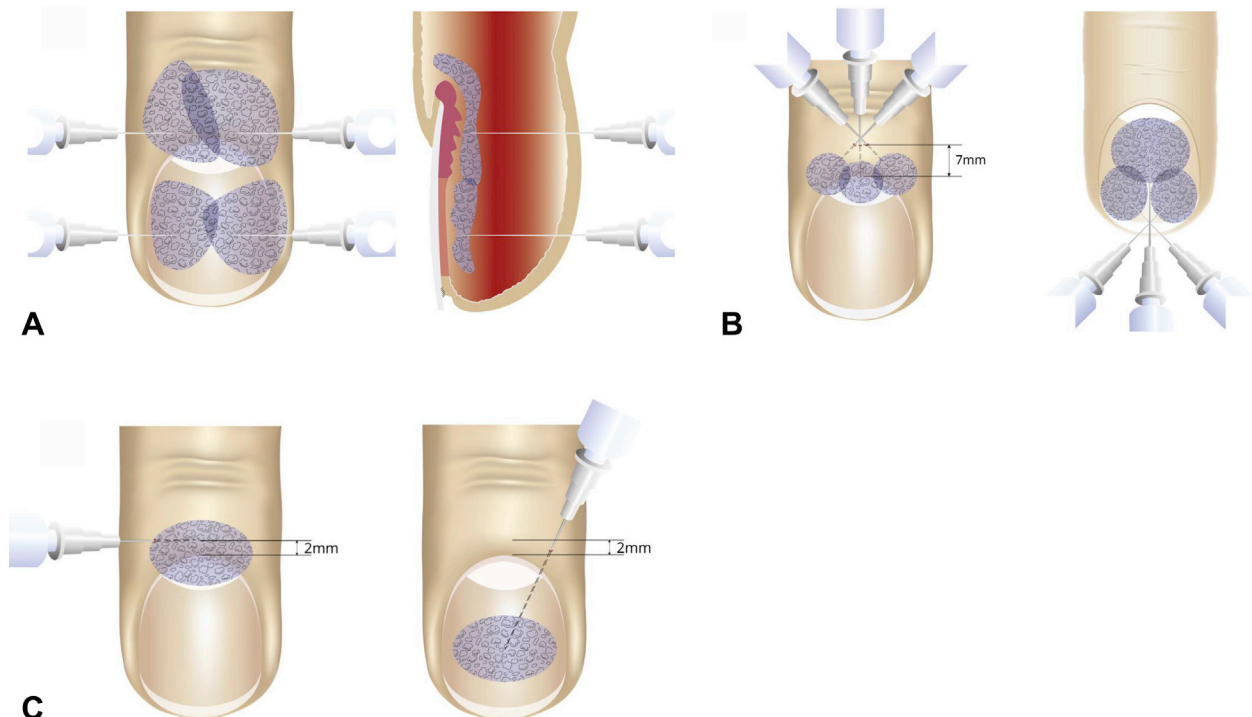


Fig 3. Intralesional matrix and bed injection techniques according to different authors. **A**, De Berker and Lawrence⁴⁰ suggest making 2 injections in the proximal nail fold, 1 injection per side, starting 2 mm proximal to the cuticle (in patients with nail matrix lichen planus [LP]) or 2 injections under the nail plate starting from the lateral folds, 1 injection per side (in nail bed LP). **B**, One of the authors of this review (Dr Richert) has used 3 injections (fan-like) starting from the median part of the proximal fold to reach the proximal matrix and its lateral horns (in patients with nail matrix LP) or 3 injections (fan-like) under the nail plate from the hyponychium to reach the whole bed (in patients with nail bed LP). **C**, Grover and Bansal⁴¹ suggest making 1 injection starting 2 mm proximal to the proximal nail fold and advancing roughly up to the middle (in patients with nail matrix LP) or 1 injection with the needle inserted slightly more medially and advanced towards the center of the nail bed. If the syringe is in parallel axis to the finger, the risk to encounter the bone is higher (in patients with nail bed LP). Illustration courtesy of Florence Richert.

active treatment phase (at least for the first 2-3 months and especially in severe cases). Caution must be taken because of systemic side effects, even if they are quite rare. Underlying conditions, such as diabetes, glaucoma, and osteoporosis, should always be ruled out. Bone protection with calcium and vitamin D should also be discussed.⁴² Treatment is continued until there is marked or complete improvement and then tapered with dosage reduced to half of the therapeutic dose. If no clinical response after 6 months is achieved, a change of treatment should be considered, and tapering is not necessary.

Oral steroids might be also an option; however, they may cause unwanted side effects because of the required high dosages kept daily for many months.⁴³ For this reason, the authors discourage their use in NLP.

For patients who refuse or who have contraindications to steroids, oral retinoids can be a valid

option. Acitretin 0.2 to 0.3 mg/kg/day⁴⁴ or alitretinoin 30 mg/day¹⁰⁻¹² are known to be effective in patients with cutaneous and oral LP, but their role in treating NLP is less known. Known side effects of retinoids include nail softening and brittleness,⁴⁵ which are unwanted in NLP-affected patients that already suffer from nail fragility. Therefore, low dosages of acitretin are always recommended, lower than those used for nail psoriasis (0.3-0.4 mg/kg/day).³⁹ Dose adjustments may be needed over time, because side effects may occur (usually 2-18 weeks after starting treatment). Retinoids are also well known to accelerate nail growth, and this is the mechanism by which they probably improve matrix NLP.⁴⁶ The desquamative effect of retinoids can instead improve the typical hyperkeratosis of nail bed LP.

Alitretinoin is known to have fewer side effects than acitretin, greater antiinflammatory properties,

and a better regulation of keratinocyte differentiation and proliferation.⁴⁷ Moreover, alitretinoin seems to reduce the susceptibility of the epidermis to friction, another factor that negatively influences nail growth in NLP. Unfortunately, alitretinoin is not available in every country.

In case of improvement, retinoids are continued until cure and only then the drug dosage is progressively reduced. If no clinical response after 6 months is achieved, a change of treatment should be considered, and tapering is not necessary. According to the authors' experience, however, mild to moderate cases however respond to retinoids much better than severe cases.

Azathioprine 100 mg/day, cyclosporine 3 to 5 mg/kg/day, or mycophenolate mofetil 1000 mg twice daily can be considered as monotherapy or as an adjunctive to steroid therapy in severe cases with poor response to steroids. Their efficacy is not well studied for NLP and the authors support their use only as a third option. However, it should be noted that patients who do not respond to a first-line therapy are unlikely to respond to other treatments. These patients should be in any case followed over time and provided with comprehensive nail care instructions, including but not limited to mechanisms of trimming their dystrophic plates, avoidance of overaggressive manicuring, and optimal moisturization of the nails.

The use of hydroxychloroquine and methotrexate is not supported as they are thought, by our group, to be ineffective. Biologics are not included in our list as there is minimal experience on their usage for NLP: they should be used off-label, as the other drugs, but the costs are far greater.

A future potential therapy may be tofacitinib, an inhibitor of the enzymes Janus kinase 1 and Janus kinase 3, which are upregulated in LP. Proinflammatory cytokines and the interferon gamma pathway are thus inhibited and CD8⁺ T-cell recruitment is reduced.⁴⁸ Tofacitinib has never been evaluated in patients with NLP, but it has been studied in patients with scalp LP who are resistant to conventional treatments, resulting in an 80% clinical improvement, either as monotherapy or as adjunctive therapy.⁴⁹ Additional studies are however necessary because the costs are high.

In conclusion, NLP should always be treated; regardless of the chosen treatment, long-term follow-up for all affected patients is advisable because relapses are common.

This review underlines the importance of early treatment because the disease course is unpredictable and often aggressive. Triamcinolone acetonide, both intralesional and intramuscular, are first-line

therapies. Oral retinoids are second-line choices, and immunosuppressive agents may also be considered.

REFERENCES

1. Samman PS. The nails in lichen planus. *Br J Dermatol*. 1961;73:288-292.
2. Chiheb S, Benchikhi H. Clinical characteristics of nail lichen planus and follow-up: a descriptive study of 20 patients. *Ann Dermatol Venereol*. 2015;142:21-25.
3. Pandhi D, Singal A, Bhattacharya SN. Lichen planus in childhood: a series of 316 patients. *Pediatr Dermatol*. 2014;31:59-67.
4. Halteh P, Scher RK, Brinster NK, Lipner SR. A 10-year-old boy with dystrophy of the fingernails. *Pediatr Dermatol*. 2017;34:193-194.
5. Iorizzo M, Lipner S. Nail lichen planus. In: Tosti A, ed. *Nail disorders*. St. Louis, Missouri: Elsevier; 2018:27-30.
6. Piraccini BM, Starace M, Misciali C, Fanti PA. Nail unit lichen planus. In: Rubin AI, Jellinek NJ, Daniel 3rd CR, Scher RK, eds. *Scher and Daniel's Nails*. 4th ed. Cham: Switzerland; Springer; 2018:127-143.
7. Daniel CR, Tosti A, Iorizzo M, Piraccini BM. The disappearing nail bed: a possible outcome of onycholysis. *Cutis*. 2005;76:325-327.
8. Grover C, Bansal S. Nail biopsy: a user's manual. *Indian Dermatol Online J*. 2018;9:3-15.
9. Lipner S. Nail lichen planus: a true nail emergency. *J Am Acad Dermatol*. 2019;80:e177-e178.
10. Pinter A, Patzold S, Kaufmann R. Lichen planus of nails—successful treatment with alitretinoin. *J Dtsch Dermatol Ges*. 2011;9:1033-1034.
11. Iorizzo M. Nail lichen planus—a possible new indication for oral alitretinoin. *J Eur Acad Dermatol Venereol*. 2016;30:509-510.
12. Alsenaid A, Ruzicka T, Braun-Falco M, Wolf R. Successful treatment of nail lichen planus with alitretinoin: report of 2 cases and review of the literature. *Dermatology*. 2014;229:293-296.
13. Butsch F, Jetter A, Schopf RE. Successful treatment of palmoplantar nail lichen planus with cyclosporine. *J Dtsch Dermatol Ges*. 2014;12:724-725.
14. Goettmann S, Zaraq I, Moulouguet I. Nail lichen planus: epidemiological, clinical, pathological, therapeutic and prognosis study of 67 cases. *J Eur Acad Dermatol Venereol*. 2012;10:1304-1309.
15. Prevost NM, English JC 3rd. Palliative treatment of fingernail lichen planus. *J Drugs Dermatol*. 2007;6:202-204.
16. Mostafa WZ. Lichen planus of the nails: treatment with antimalarials. *J Am Acad Dermatol*. 1989;20:289-290.
17. Irla N, Schneiter T, Haneke E, Yawalkar N. Nail lichen planus: successful treatment with etanercept. *Case Rep Dermatol*. 2010;2:173-176.
18. Kato N, Ueno H. Isolated lichen planus of the nails treated with tretinoin. *J Dermatol*. 1993;20:577-580.
19. Manousaridis I, Manousaridis K, Peitsch WK, Schneider SW. Individualizing treatment and choice of medication in lichen planus: a step by step approach. *J Dtsch Dermatol Ges*. 2013;11:981-991.
20. Banga G, Patel K. Glicolic acid peel for nail rejuvenation. *J Cutan Aesthet Surg*. 2014;7:198-201.
21. Daulatabad D, Nanda S, Grover C. Intra-individual right-left comparative study of medium depth peels in superficial nail abnormalities. *J Cutan Aesthet Surg*. 2017;10:28-32.
22. Takeuchi Y, Iwase N, Suzuki M, Tsuyuki S. Lichen planus with involvement of all twenty nails and the oral mucous membrane. *J Dermatol*. 2000;27:94-98.

23. Tosti A, Peluso AM, Fanti PA, Piraccini BM. Nail lichen planus: clinical and pathologic study of twenty-four patients. *J Am Acad Dermatol*. 1993;28:724-730.
24. Ujjie H, Shibaki A, Akiyama M, Shimizu H. Successful treatment of nail lichen planus with topical tacrolimus. *Acta Derm Venereol*. 2010;90:218-219.
25. Abell E, Samman PD. Intradermal triamcinolone treatment of nail dystrophies. *Br J Dermatol*. 1973;89:191-197.
26. Grover C, Bansal S, Nanda S, Reddy BS. Efficacy of triamcinolone acetonide in various acquired nail dystrophies. *J Dermatol*. 2005;32:963-968.
27. Gerstein W. Psoriasis and lichen planus of nail: treatment with triamcinolone. *Arch Dermatol*. 1962;86:419-421.
28. Piraccini BM, Sacconi E, Starace M, Balestri R, Tosti A. Nail lichen planus: response to treatment and long term follow-up. *Eur J Dermatol*. 2010;20:489-496.
29. Brauns B, Stahl M, Schön MP, Zutt M. Intralesional steroid injection alleviates nail lichen planus. *Int J Dermatol*. 2011;50:626-627.
30. Tosti A, Piraccini BM, Cambiaghi S, Iorizzo M. Nail lichen planus in children: clinical features, response to treatment, and long-term follow-up. *Arch Dermatol*. 2001;137:1027-1032.
31. Sibling SM. Observations on growth of fingernails in health and disease. *Pediatrics*. 1959;24:225-233.
32. Deffer TA, Goette DK. Distal phalangeal atrophy secondary to topical steroid therapy. *Arch Dermatol*. 1987;123:571-572.
33. Wenzel J, Scheler M, Proelss J, Bieber T, Tuting T. Type I interferon-associated cytotoxic inflammation in lichen planus. *J Cutan Pathol*. 2006;33:672-678.
34. Di Lernia V. Targeting the IFN- γ /CXCL10 pathway in lichen planus. *Med Hypotheses*. 2016;92:60-61.
35. Woon CY, Phoon ES, Lee YJ, Ng SW, Teoh LC. Hazards of steroid injection: suppurative extensor tendon rupture. *Indian J Plast Surg*. 2010;43:97-100.
36. Baran R. Proximal nail fold steroid injection responsible for Hoignè syndrome. *J Eur Acad Dermatol Venereol*. 2014;28:1563-1565.
37. Grover C, Kharghoria G, Daulatabad D, Bhattacharya SN. Nicolau syndrome following intramatrix triamcinolone injection for nail lichen planus. *Indian Dermatol Online J*. 2017;8:350-351.
38. Clark A, Jellinek N. Intralesional injections for inflammatory nail diseases. *Dermatol Surg*. 2016;42:257-260.
39. Rigopoulos D, Baran R, Chiheb S, et al. Recommendations for the definition, evaluation, and treatment of nail psoriasis in adult patients with no or mild skin psoriasis: a dermatologist and nail expert group consensus. *J Am Acad Dermatol*. 2019;81:228-240.
40. De Berker DA, Lawrence CM. A simplified protocol of steroid injection for psoriatic nail dystrophy. *Br J Dermatol*. 1998;138:90-95.
41. Grover C, Bansal S. A compendium of intralesional therapies for nail disorders. *Indian Dermatol Online J*. 2018;9:373-382.
42. Caplan A, Fett N, Rosenbach M, Werth VP, Micheletti RG. Prevention and management of glucocorticoid-induced side effects: a comprehensive review: a review of glucocorticoid pharmacology and bone health. *J Am Acad Dermatol*. 2017;76:1-9.
43. Roger L. Serious adverse events with low-dose, long-term corticosteroid therapy in rheumatoid arthritis. *Am J Med*. 1995;99:692-694.
44. Baran R. Retinoids and the nails. *J Dermatol Treat*. 1990;1:151-154.
45. Baran R. Action thérapeutique et complications du rétinoïde aromatique sur l'appareil ungueal. *Ann Dermatol Venereol*. 1982;109:367-371.
46. Galosi A, Plewig G, Braun-Falco O. The effects of etretinate on fingernail growth. *Arch Dermatol Res*. 1985;277:138-140.
47. Cheng C, Michaels J, Scheinfeld N. Alitretinoin: a comprehensive review. *Expert Opin Invest Drugs*. 2008;17:437-443.
48. Alves de Medeiros AK, Speeckaert R, Desmet E, Van Gele M, De Schepper S, Lambert J. JAK3 as an emerging target for topical treatment of inflammatory skin diseases. *PLoS One*. 2016;11:e0164080.
49. Yang CC, Khanna T, Sallee B, Christiano AM, Bordone LA. Tofacitinib for the treatment of lichen planopilaris: a case series. *Dermatol Ther*. 2018;31:e12656.