



Euroderm 2024

Budapest, Hungary

---

Dr David Brass

Consultant Dermatologist and Mohs surgeon

Department of Dermatology

RVI Newcastle





# Aims


- Looking after yourself
  - Surgical pearls
- Surgical closures


# Posture


[Home](#) > [Blogs](#) > [Ergonomics in Surgery – The Athlete in the Operating Room](#)

 Blog

## Ergonomics in Surgery – The Athlete in the Operating Room

 March 16, 2021

 Barbara Hamilton, MD, Mohammed Dairywala & Tom C. Nguyen, MD

 5 min read

 [Surgeon](#) • [Career Development Blog](#) • [Early Career](#)

- Vitally important and rarely talked about
- Musculoskeletal longevity
- *Standing posture*
- *Sitting posture*
- *Operating posture*
- [Posture demonstration](#)






# Take home

- Practice your posture **as often as you can**– it can take weeks – if not months
- Invest in a pair of lightweight loupes – measured to fit
- Consider a wearable posture corrector
- Consider a saddle seat either at desk or when operating




# Hyfreccation

▶ J Cutan Aesthet Surg. 2019 Jan-Mar;12(1):1–7. doi: [10.4103/JCAS.JCAS\\_177\\_18](https://doi.org/10.4103/JCAS.JCAS_177_18) 

## **Surgical Smoke in Dermatology: Its Hazards and Management**

[Saloni Katoch](#) <sup>1,✉</sup>, [Venkataram Mysore](#) <sup>1</sup>

▶ Clin Exp Dermatol. 2020 Oct 1;45(7):841–847. doi: [10.1111/ced.14350](https://doi.org/10.1111/ced.14350) 

## **Surgical plume in dermatology: an insidious and often overlooked hazard**

[T Searle](#) <sup>1</sup>, [F R Ali](#) <sup>2,3</sup>, [F Al-Niimi](#) <sup>4,5,✉</sup>

Tomita *et al.* found that the amount of smoke condensates produced from 1 g of tissue using a CO<sub>2</sub> laser and electrocautery was equivalent to that of three and six cigarettes, respectively.<sup>17</sup> Another study reported that daily plume generated from monopolar electrocautery on human and porcine muscle tissue was equivalent to 27–30 cigarettes.<sup>18</sup>

## Conclusion

---

Surgical plumes potentially have toxic, carcinogenic and infectious capacity. Surgical masks confer little protection to the respiratory tract against aerosols generated during surgery or CO<sub>2</sub> laser procedures. To reduce the quantity of plume generated, operators should consider using bipolar (as opposed to unipolar or monopolar) cautery at the lowest power settings. Mechanisms to remove the generated plumes through vacuum extraction should be implemented, as well as the use of appropriate personal protective equipment.



# Therapeutic use of self

**Opinion** » Talking Point

## John Launer: Putting on a performance

*BMJ* 2024 ; 384 doi: <https://doi.org/10.1136/bmj.q364> (Published 14 February 2024)

Cite this as: *BMJ* 2024;384:q364

JOURNAL ARTICLE

## In the performing art of medicine: the doctor as actor [Get access >](#)

P.J. Whorwell, F. Shanahan

► *J R Soc Med.* 2005 Jul;98(7):323–324. doi: [10.1258/jrsm.98.7.323](https://doi.org/10.1258/jrsm.98.7.323) [↗](#)

## Doctors as performance artists

[Michael O'Donnell](#)<sup>1</sup>

<https://www.theothub.com/article/therapeutic-use-of-self>

# Take home

- Smile, be welcoming and give a little of yourself
- Try to build rapport – be reassuring and don't take away hope
  - Attunement
  - Unconditional positive regard
  - Self-disclosure
  - Balancing the power differential

**'They may forget what you said - but they will never forget how you made them feel' - Carl Beuhner**

# Sodium bicarbonate

► [Cureus. 2023 Apr 21;15\(4\):e37934. doi: 10.7759/cureus.37934](#)

## Efficacy of Sodium Bicarbonate-Buffered Local Anesthetic Solution in Cases Requiring Bilateral Maxillary Premolar Orthodontic Extraction: A Comparative Split-Mouth Study

[Mohamed Umer E Valiulla](#)<sup>1,✉</sup>, [Rajshekhar Halli](#)<sup>1</sup>, [Saurabh Khandelwal](#)<sup>1</sup>, [Ananya Mittal](#)<sup>1</sup>, [Akanksha Singh](#)<sup>1</sup>, [Kajal Bhindora](#)<sup>1</sup>

Comparison of buffered and non-buffered lidocaine: pH and pain perception

Open Access



Authors: [Vandana Sadananda](#), [Jubana M K](#), [Mithra N. Hegde](#), [Aditya Shetty](#), [Priya Gatti](#)

[View Affiliations](#)

Published online on: September 19, 2022 <https://doi.org/10.3892/wasj.2022.172>

Article Number: 37

Copyright: © Sadananda et al. This is an open access article distributed under the terms of Creative Commons Attribution License.

September-October 2022  
Volume 4 Issue 5  
Print ISSN: 2632-2900  
Online ISSN: 2632-2919  
[Sign up for eToc alerts](#)  
[Recommend to Library](#)

JAAD ONLINE · Volume 85, Issue 1, E23, July 2021

Response to: “Cost analysis of the use of buffered lidocaine 1%, epinephrine 1:100,000 with sodium bicarbonate in a 3:1 ratio”

[Jürg Hafner, MD](#)

[Affiliations & Notes](#) ▾ [Article Info](#) ▾ [Linked Articles \(1\)](#) ▾

► [Can J Plast Surg. 2012 Summer;20\(2\):71–73. doi: 10.1177/229255031202000207](#)

Show available content in: [English](#) | [French](#)

**How acidic is the lidocaine we are injecting, and how much bicarbonate should we add?**

[Simon G Frank](#)<sup>1</sup>, [Donald H Lalonde](#)<sup>2,✉</sup>

POEMS  
Patient-Oriented Evidence That Matters

Buffering Lidocaine 1%/Epinephrine with Sodium Bicarbonate in a 3:1 Ratio Is as Effective and Less Painful than a 9:1 Ratio

PDF Print Comments

[Am Fam Physician. 2021;103\(2\)online](#)

# Tranexamic acid

## COMMUNICATIONS

### “How We Do It: Tranexamic Acid Injection for Patients on Anticoagulant Therapy”

Selby, Thomas MD<sup>†</sup>; Call, Whitney MD<sup>†</sup>; Donnelly, Heidi MD<sup>†</sup>

[Author Information](#)

*Dermatologic Surgery* 49(5):p 529-530, May 2023. | DOI: 10.1097/DSS.00000000000003769

RESEARCH LETTER · Volume 91, Issue 3, P542-544, September 2024

Subcutaneous injection of tranexamic acid reduces postoperative bleeding following Mohs micrographic surgery: A single-institution cohort study

[Nicole Loranger, BS](#) · [Emily Karn, MS](#) · [Jacob Anderson, PhD](#) · ... · [Chrysalynne Schmults, MD, MSCE](#) · [Emily Ruiz, MD, MPH](#) · [Abigail Waldman, MD](#)   ... [Show more](#)

[Affiliations & Notes](#)  [Article Info](#) 

[> Dermatol Surg.](#) 2024 Sep 5. doi: 10.1097/DSS.00000000000004373. Online ahead of print.


### Tranexamic Acid in Mohs Micrographic Surgery: A Systematic Review



[Eenika A Kumar](#)<sup>1</sup>, [Lisa M Morris](#)<sup>2</sup>, [Basia M Michalski-McNeely](#)<sup>2</sup>

[Affiliations](#) + expand

PMID: 39235116 DOI: 10.1097/DSS.00000000000004373


 [Access Options](#)

FULL TEXT LINKS

 [Full Text](#)

ACTIONS

 [Cite](#)

 [Collections](#)



# Periosteal tacking/pexing sutures

JAAD ONLINE: CLINICAL PEARL · Volume 89, Issue 2, E777-E78, August 2023

[Download Full Issue](#)

## Periosteal tacking sutures to facilitate primary repair of eyebrow-adjacent Mohs defects

[Kevin Y. Shi, MD, PhD<sup>a</sup>](#) · [Andrew J. Matsumoto, MD<sup>b</sup>](#) · [Rajiv I. Nijhawan, MD<sup>a</sup>](#)  



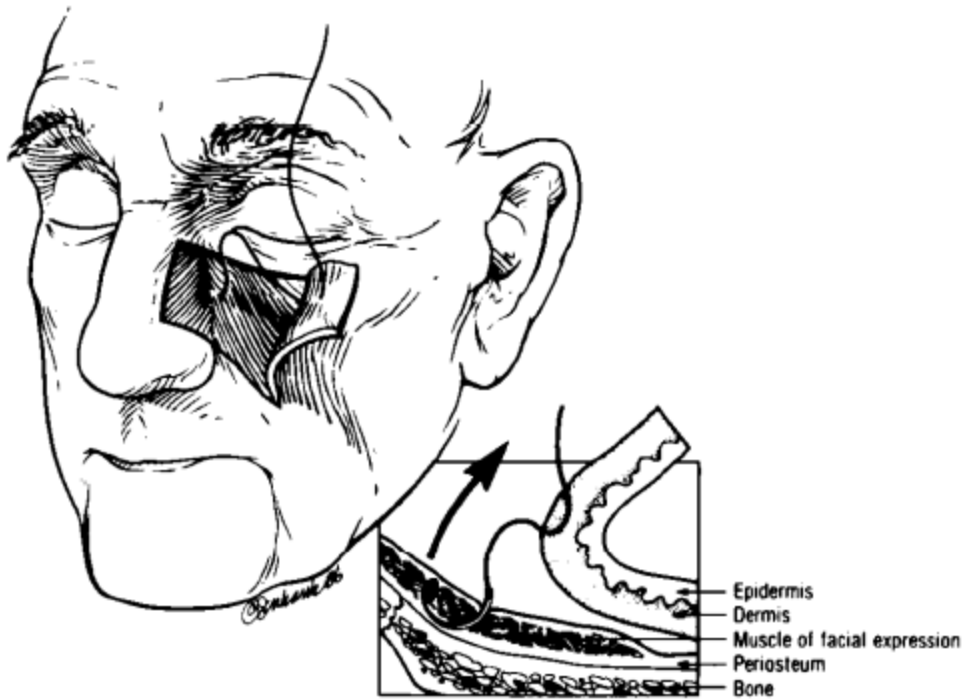
### LETTERS AND COMMUNICATIONS

## Refining the “Pin-Point Technique” for Pexing Sutures in Facial Reconstructive Surgery

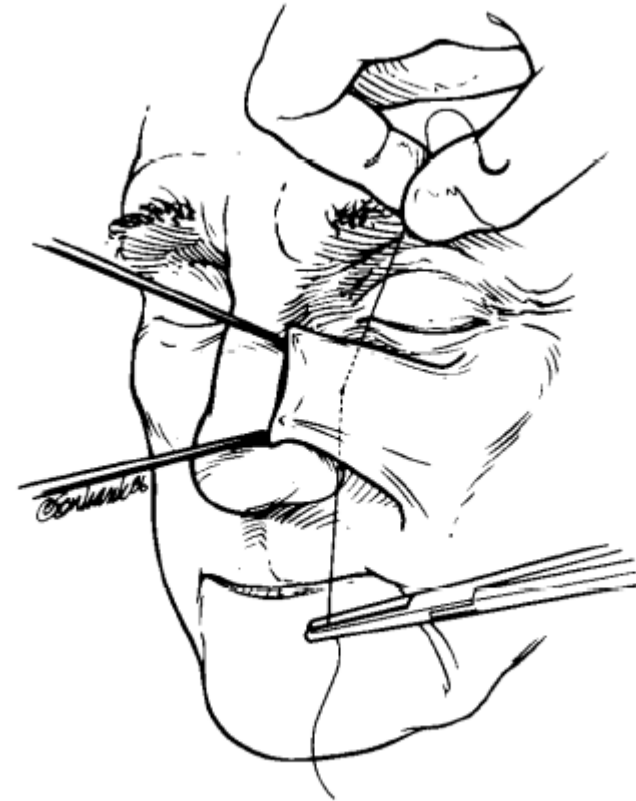
Nelson, Toby MBBS, BSc Hons, MRCP (UK), Derm; Mortimer, Neil MBChB, BSc, Hons, FRCP (UK), FRACP, FACMS;  
Salmon, Paul BChB, MBChB, FRACP, FACMS

[Author Information](#) 

*Dermatologic Surgery* 46(1):p 135-136, January 2020. | DOI: 10.1097/DSS.0000000000001873



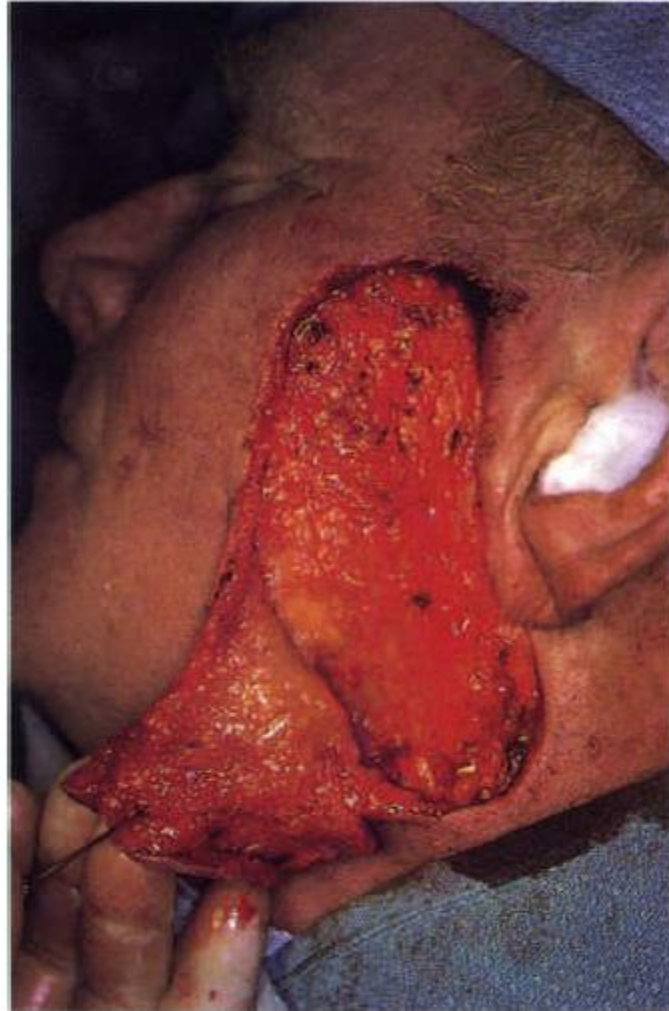
**FIGURE 1.** Suture placement parallel to flap axis. Inset— demonstration of adequate periosteal bite.



**FIGURE 2.** Use of assistant to relieve tension as knot is secured.

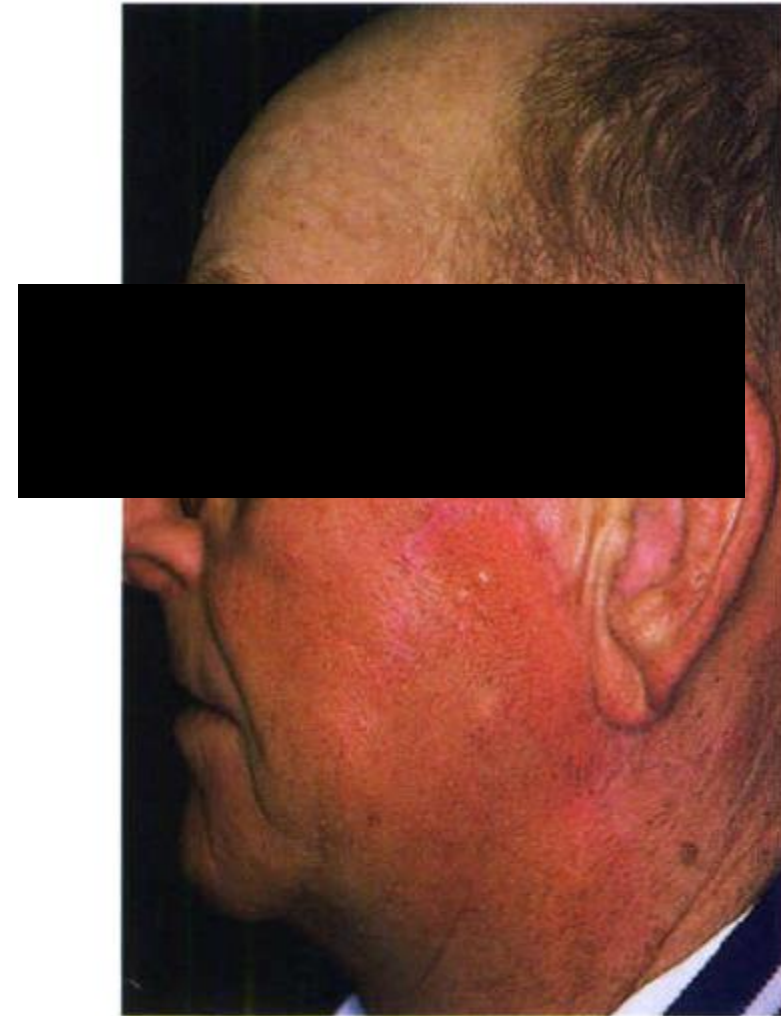Salasche SJ, Jarchow R, Feldman BD, Devine-Rust MJ, Adnot J. The suspension suture. *Journal of Dermatologic Surgery & Oncology* 1987; **13**(9):973-8

# Redirect tension



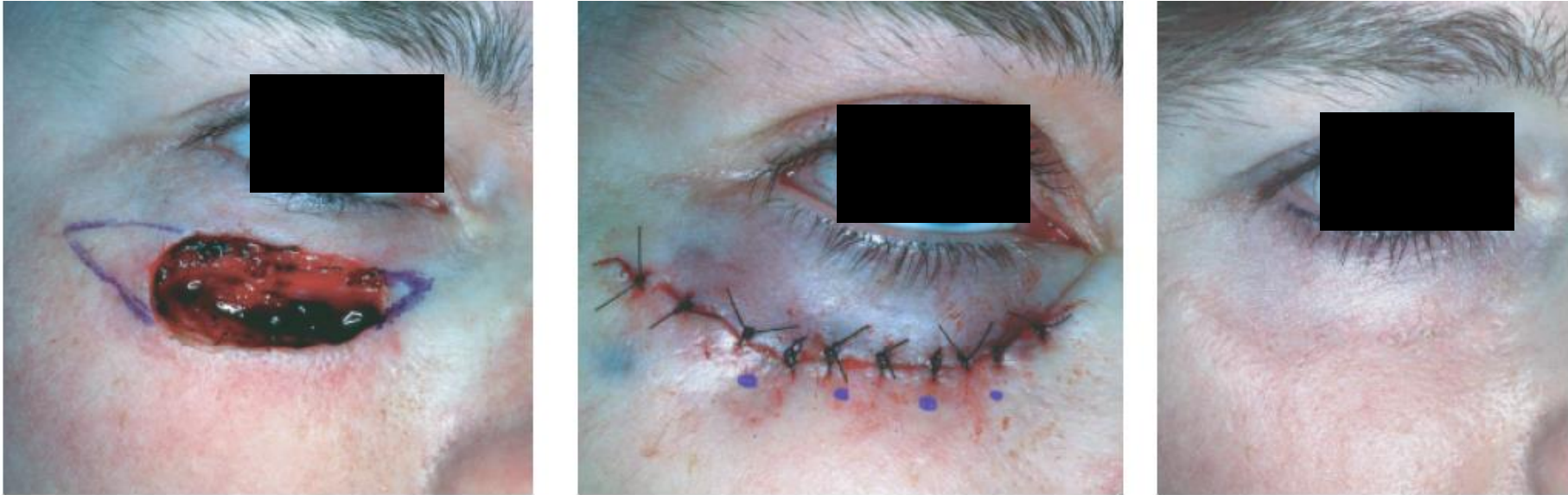**FIGURE 4A.** Large, heavy rotation flap.

*J. Dermatol. Surg. Oncol.* 13:9 September 1987



**FIGURE 4C.** Healing at 1 year.

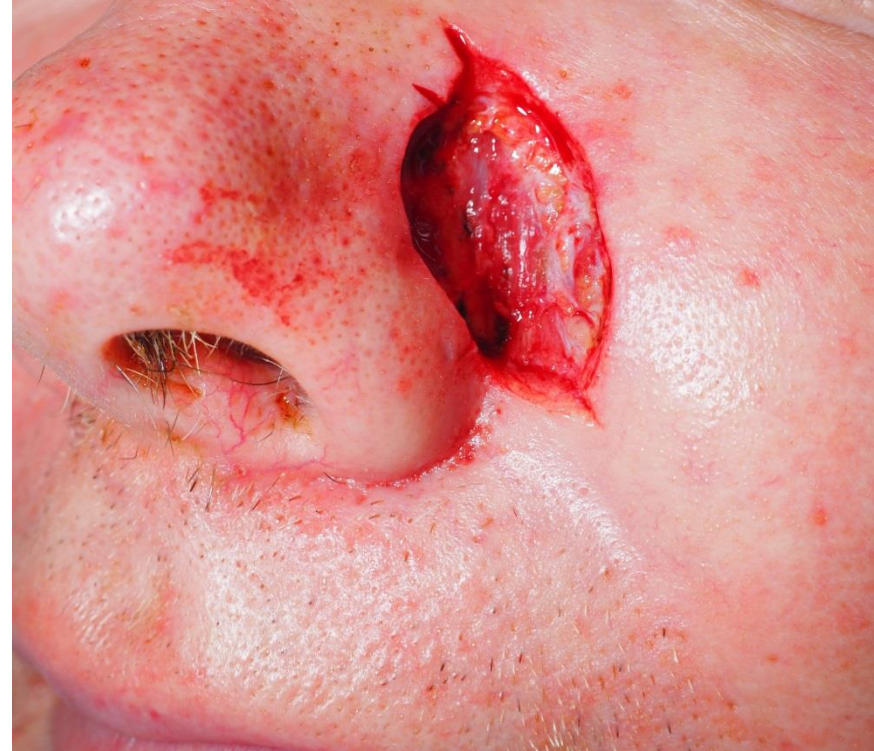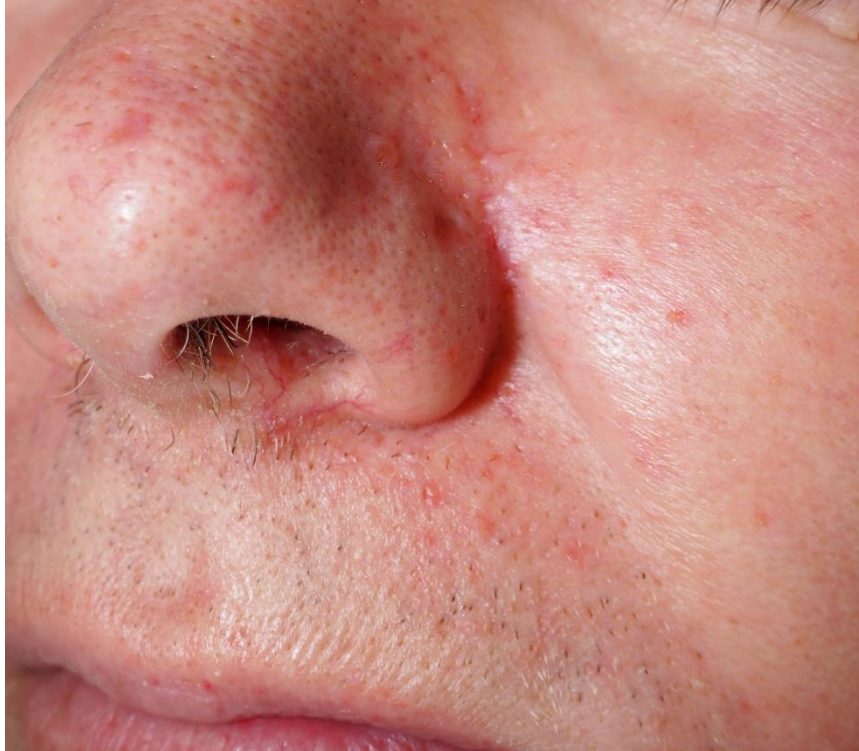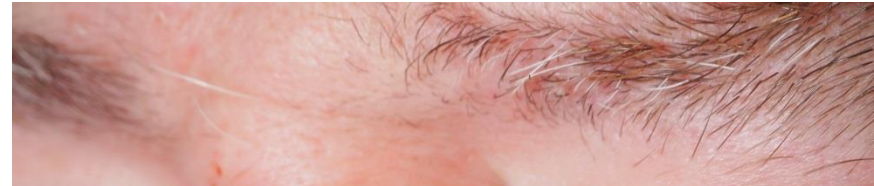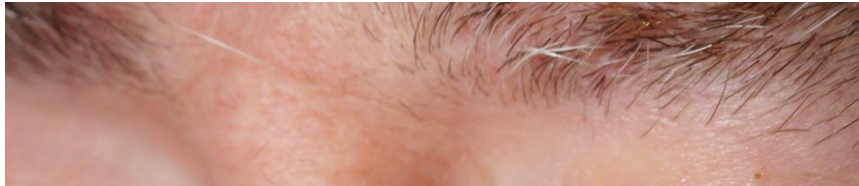# Alter tension vector



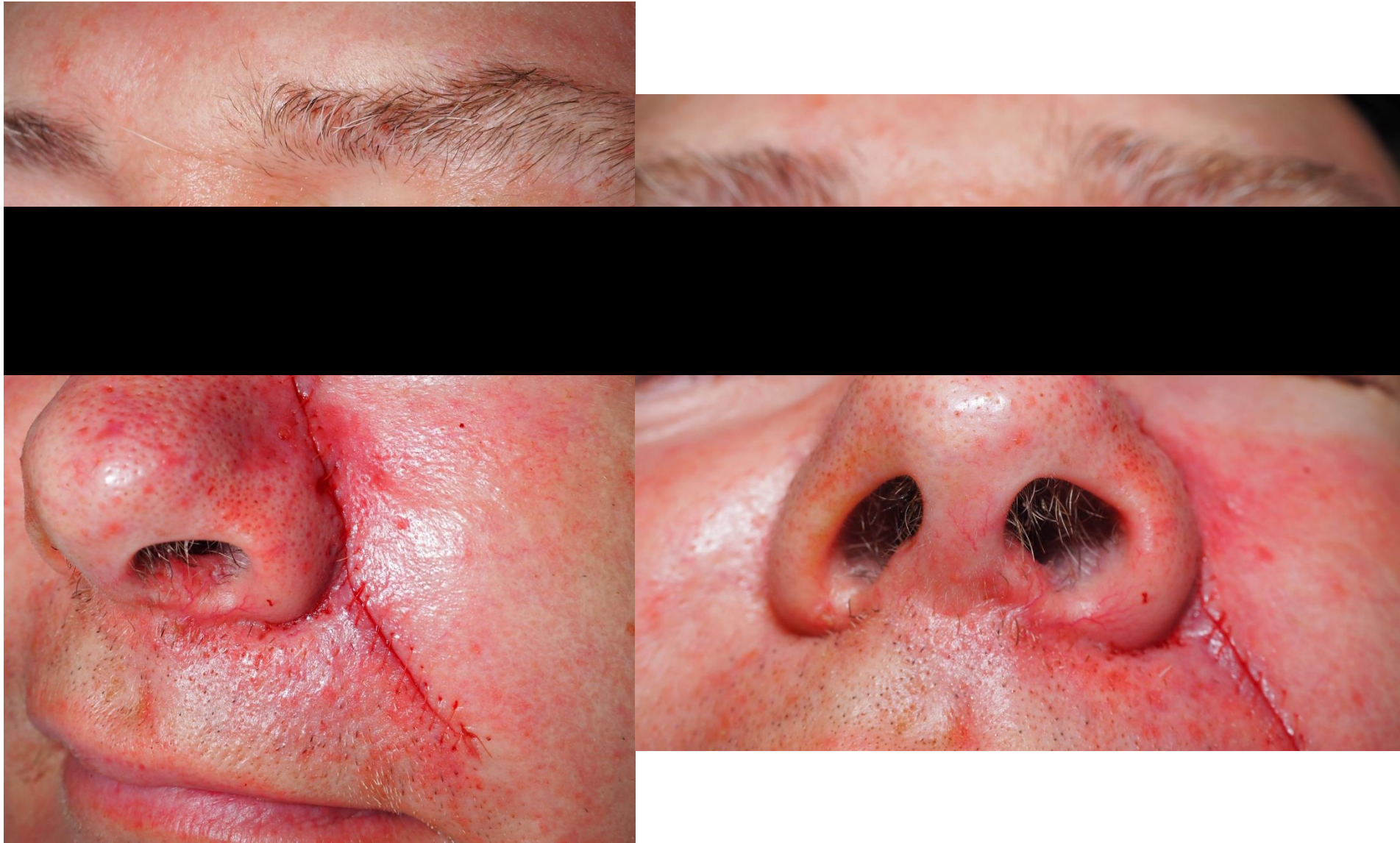
**Figure 4.** Lower eyelid cheek junction with multiple suspension sutures achieving a linear closure. Four suspension sutures (blue dots) start in the deep subcutaneous/muscle of cheek and attach to fascia and periosteum, but not into eyelid skin. One year after surgery, the curvilinear incision conforms to the contours of the junction of the cosmetic units. The lower eyelid is in proper position, and the rounded contour of the cheek is restored.

Robinson JK. Suspension sutures in facial reconstruction. *Dermatol Surg* 2003; **29**:386-393

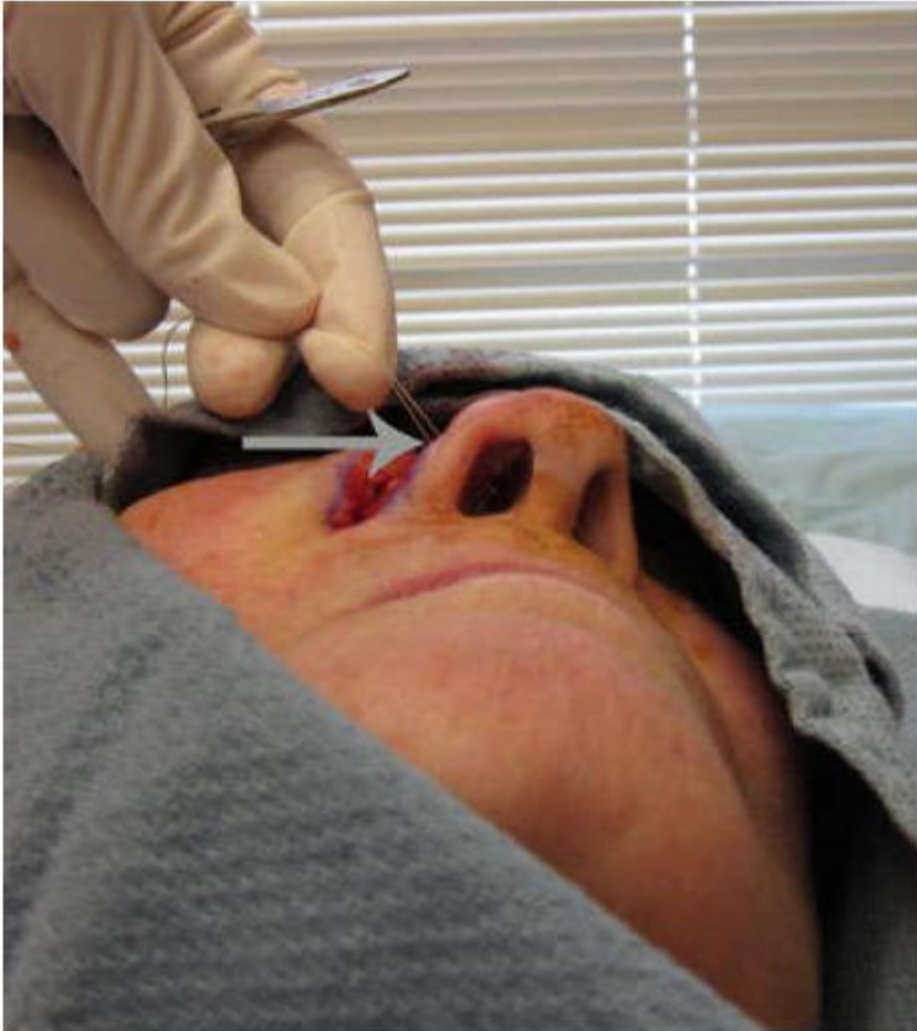# Reform skin folds



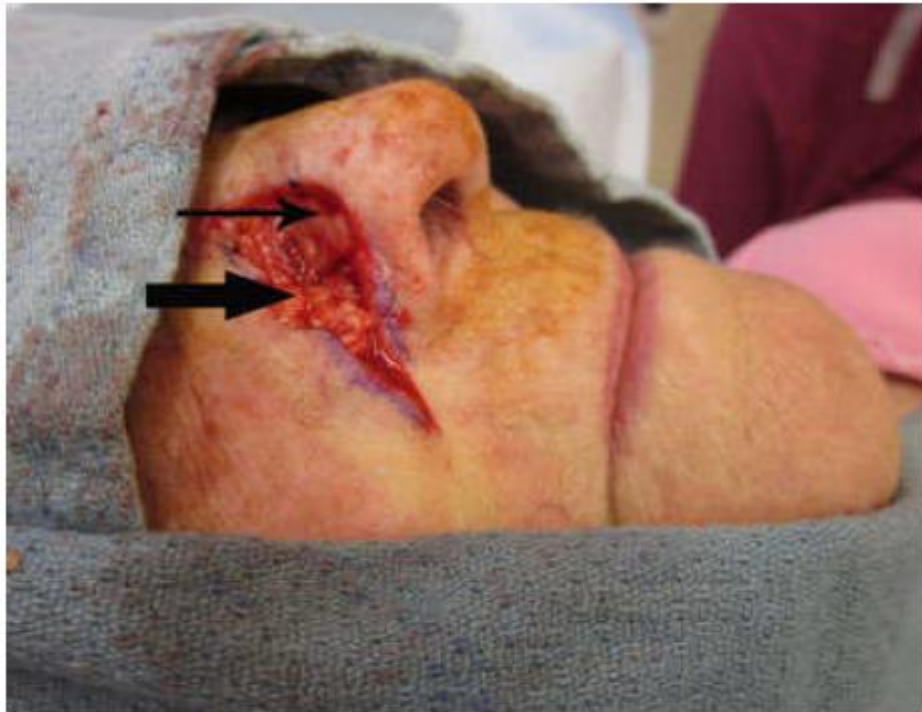# Reform skin folds



# Maintain nasal valve patency



**Figure 2.** Suture placed at point of depression (arrow) results in patent nasal valve.

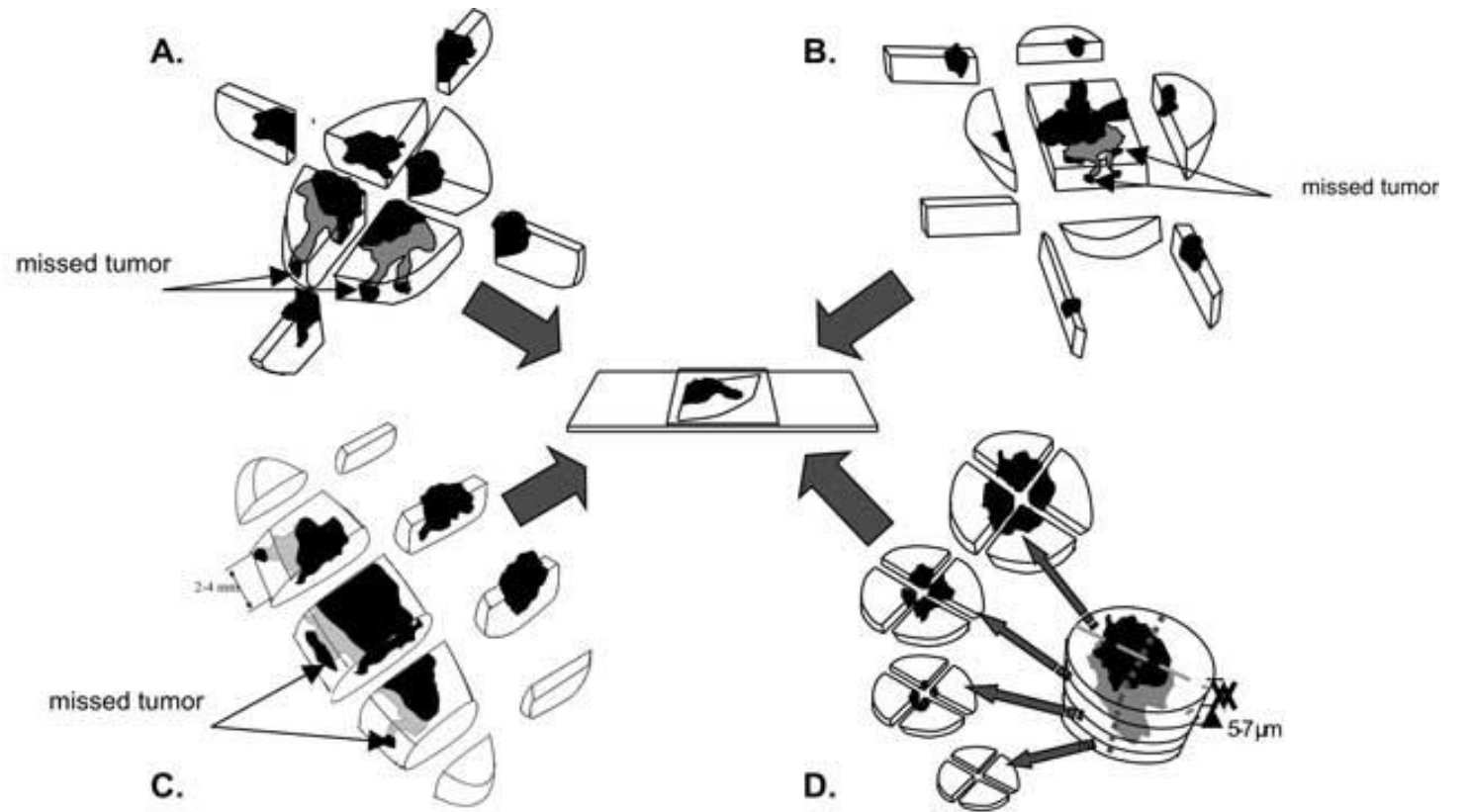


**Figure 3.** Suture has been placed through nasal tissue (thin arrow) and anchored in maxillary periosteum (thick arrow).

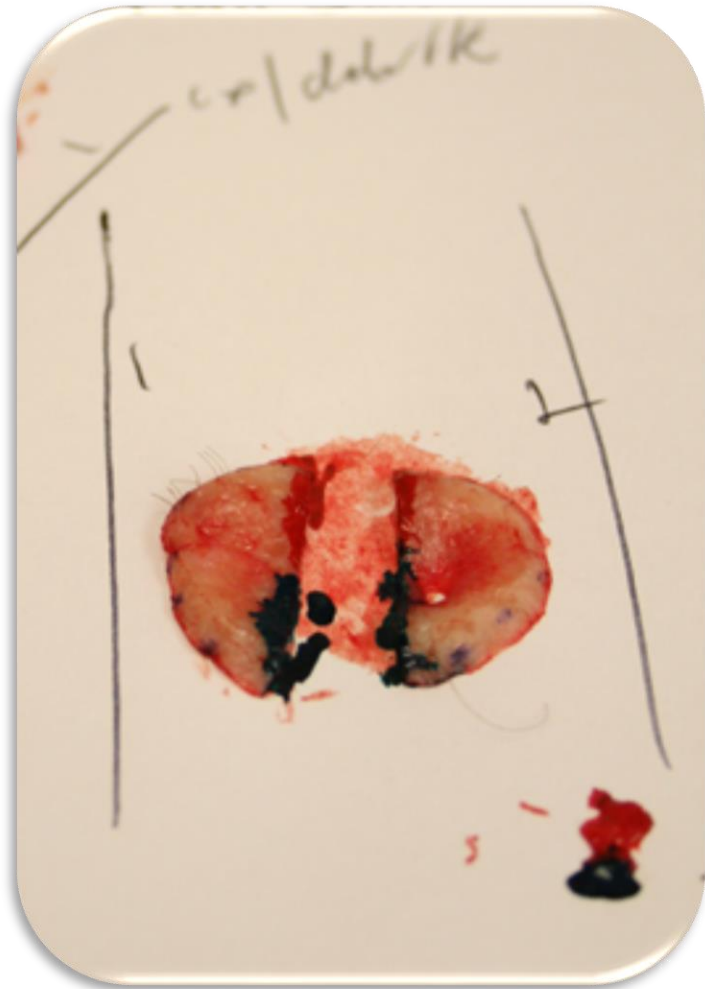Wang JH, Finn D, Cummins DL. Suspension suture technique to prevent nasal valve collapse after Mohs micrographic surgery. *Dermatol Surg* 2014; **40**(3):345-7

# Mohs surgery

“A surgical technique allowing precise microscopic control of tumour margins by utilising tangentially cut frozen section histology”

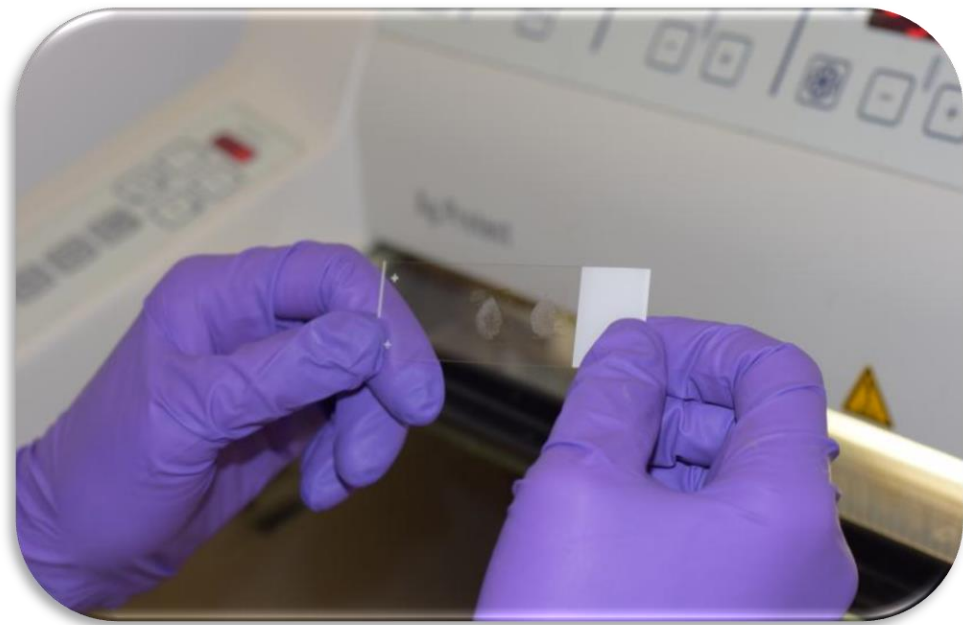
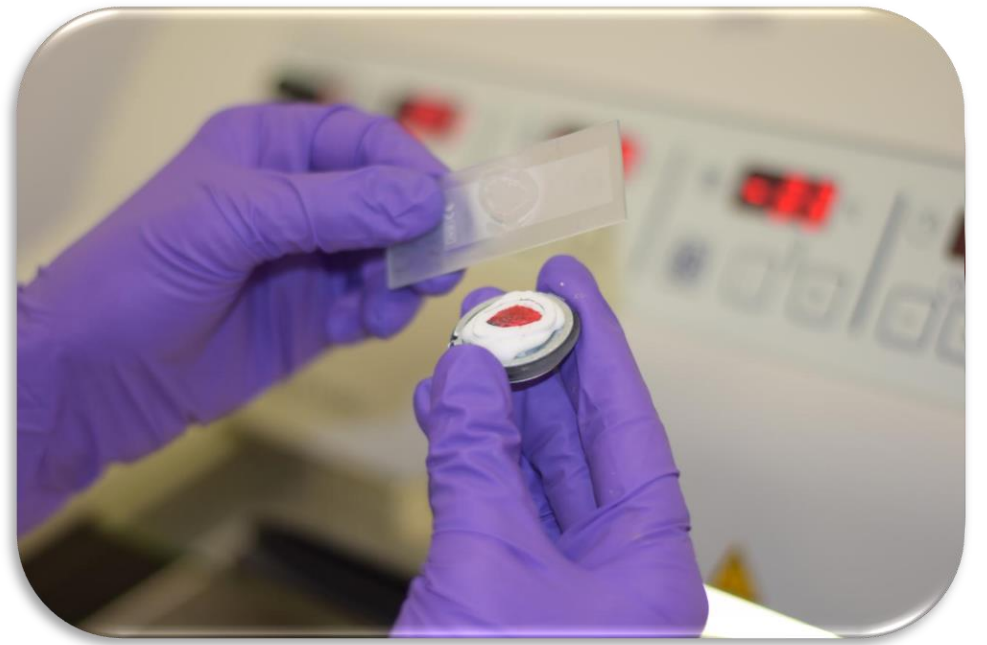


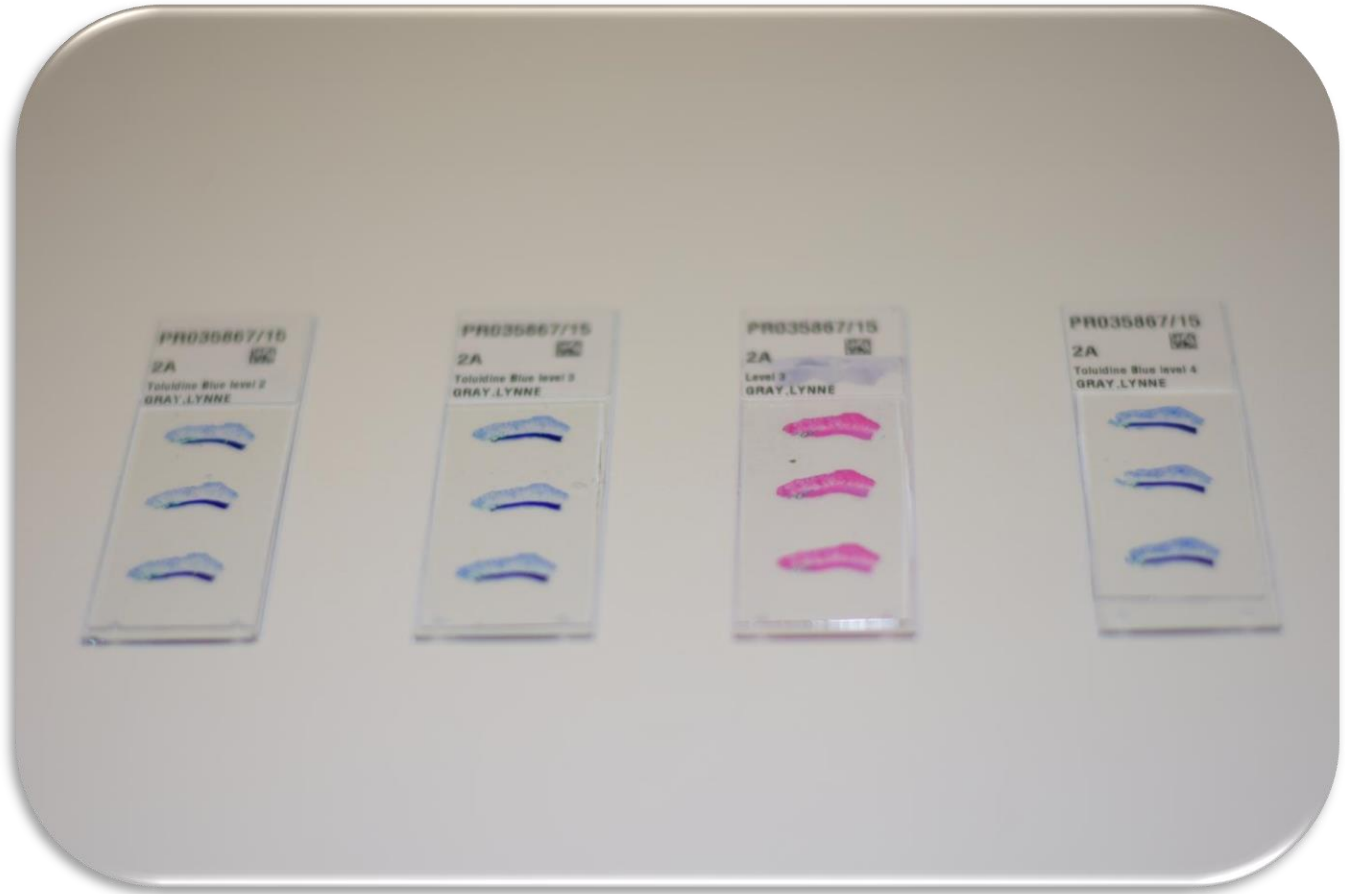


- Specimens are bisected across the 'nicks' into 2 or more 'blocks'
- Orientation maintained by 'inking' the cut edges









Surgical  
closures



























