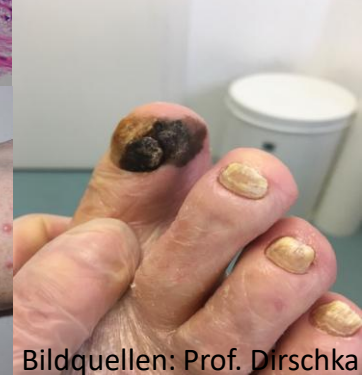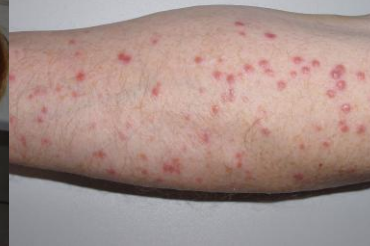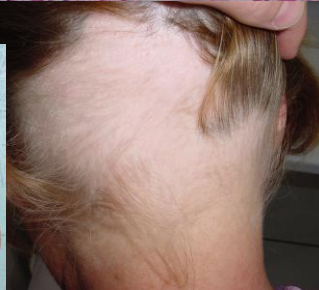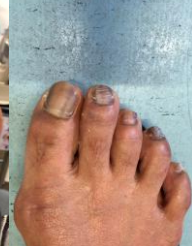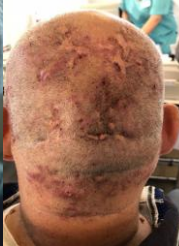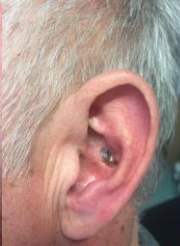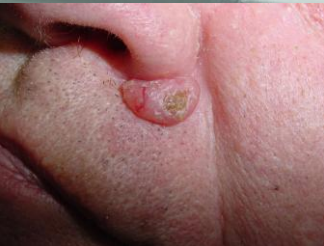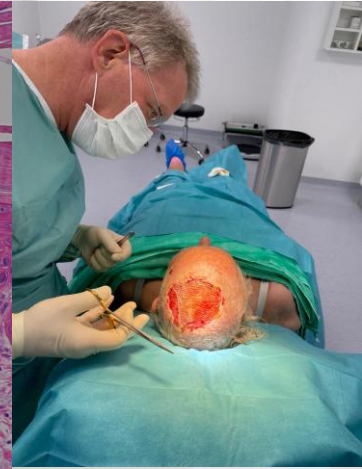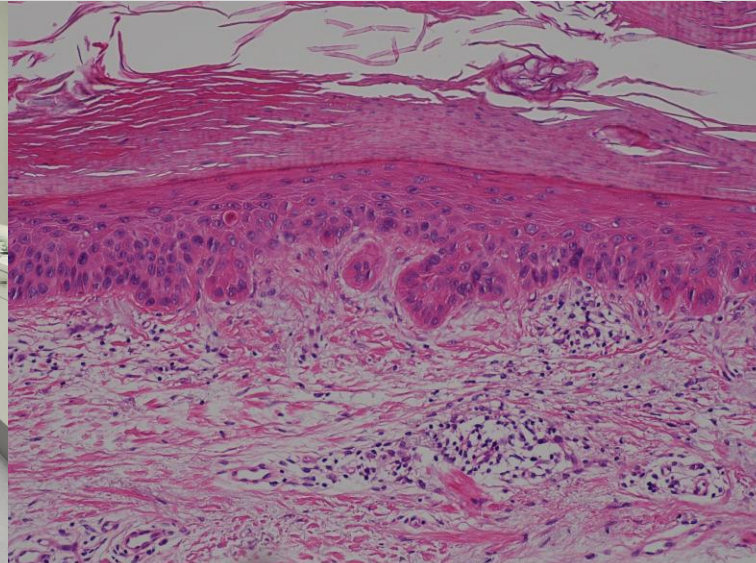


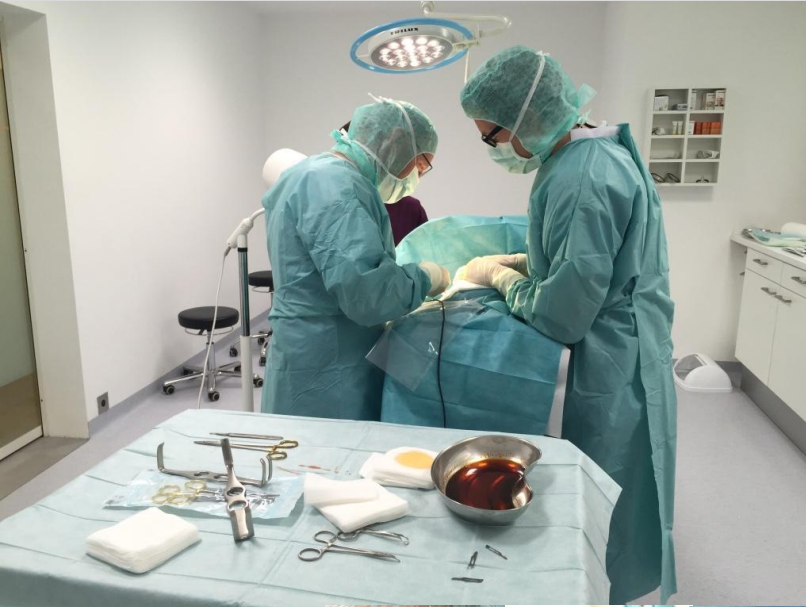Round table - discuss interesting treatment insights

Thomas Dirschka, Wuppertal





Research Support: Abbvie, Almirall, Biofrontera, Damae, Emblation, Galderma, Intros, ISDIN, La Roche Posay, L'Óreal, Mylan, Nordberg, Olistic, Schulze & Böhm GmbH, Scibase S.A., Smartinmedia AG, Speclipse, Vichy

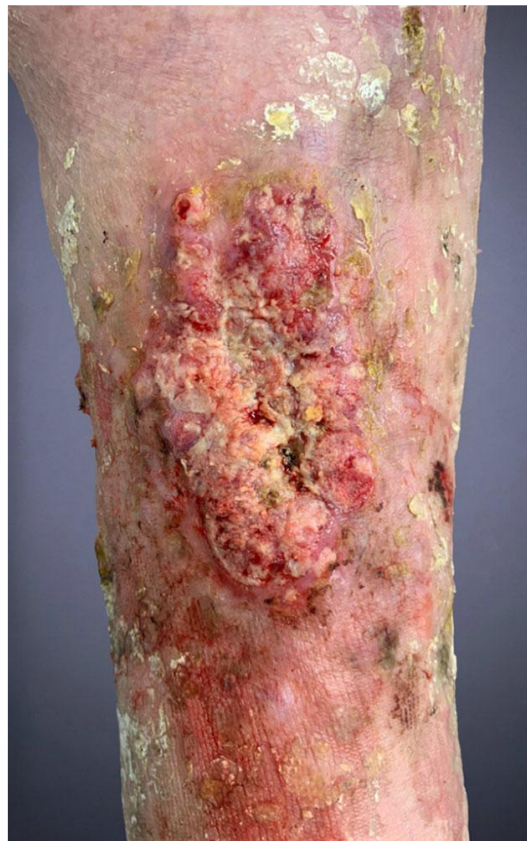Lecture Support: Abbvie, Aesclepiion, Almirall, Biofrontera, Celtrion, Damae, Dr. August Wolff, Galderma, GSK, Infectopharm, Intros, Janssen-Cilag, Leo, Louis Widmer, Mylan, Neracare, Novartis, Pierre Fabre, Pfizer, Riemsers, Speclipse, UCB

Advisory Boards: Almirall, Beiersdorf, Biofrontera, GSK, Dr. Pfleger, Galderma, Janssen-Cilag, Leo, Mylan, Neracare, Novartis, Pierre Fabre, Scibase, Smartinmedia AG, Vichy

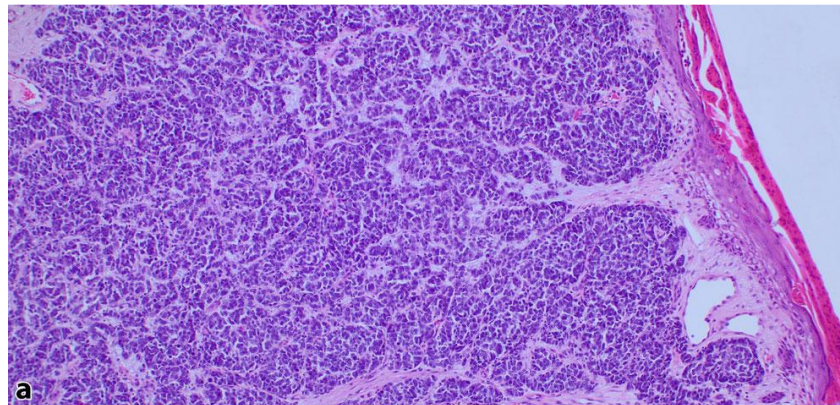


Case I

90-year-old patient What is it? What to do?

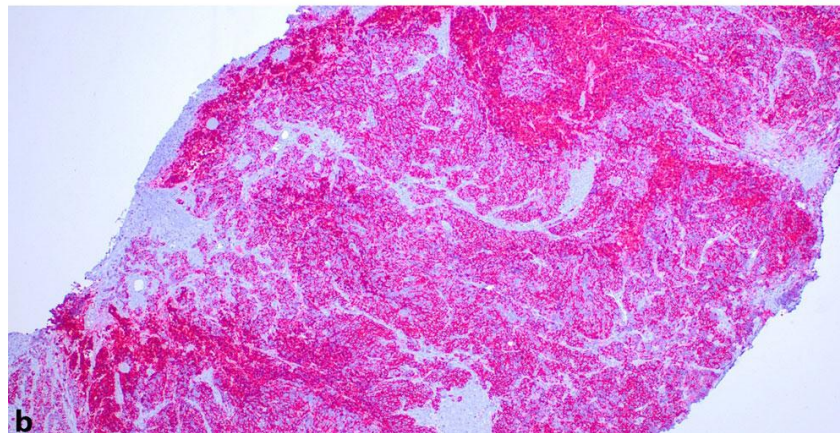


90-year-old patient



a

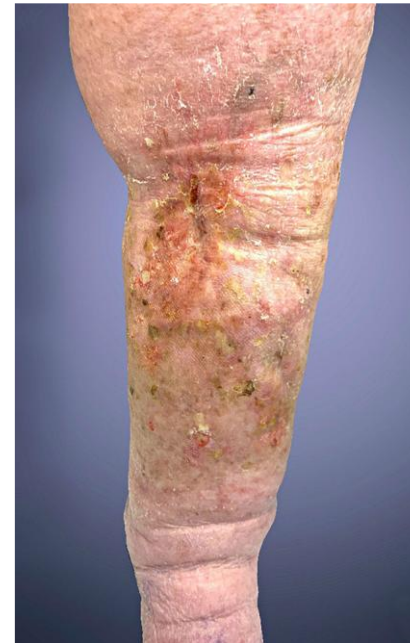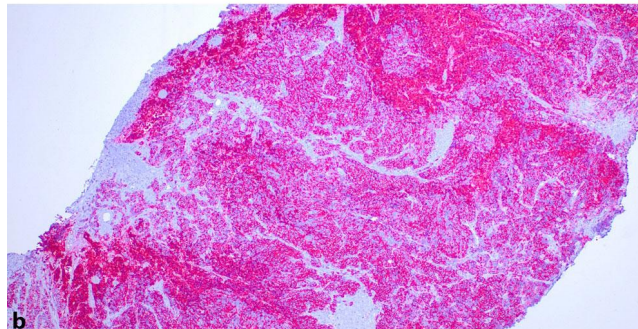
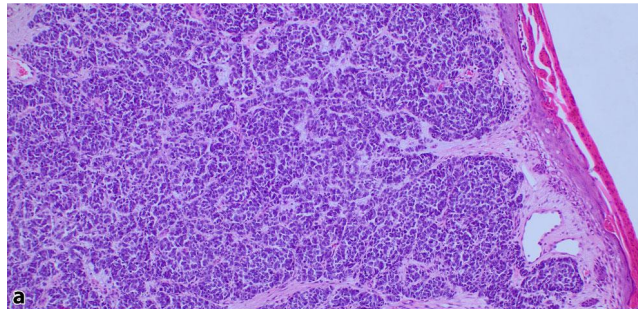
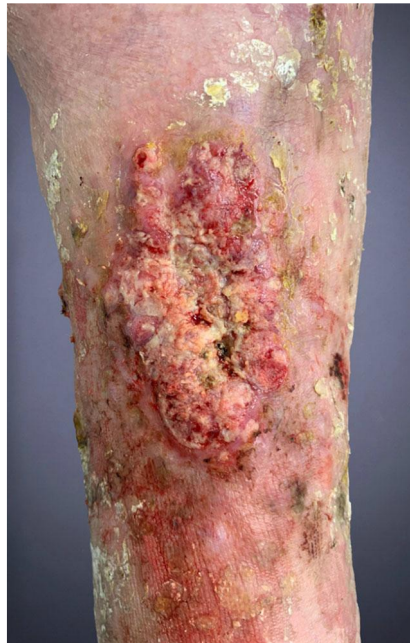H&E, x20



b

CK 20, x20

90-year-old patient
Avelumab (PD-L1), 6 cycles, every 2 weeks





Der Hautarzt

Kasuistiken

Hautarzt

<https://doi.org/10.1007/s00105-021-04799-0>

Angenommen: 2. März 2021

© Springer Medizin Verlag GmbH, ein Teil von
Springer Nature 2021



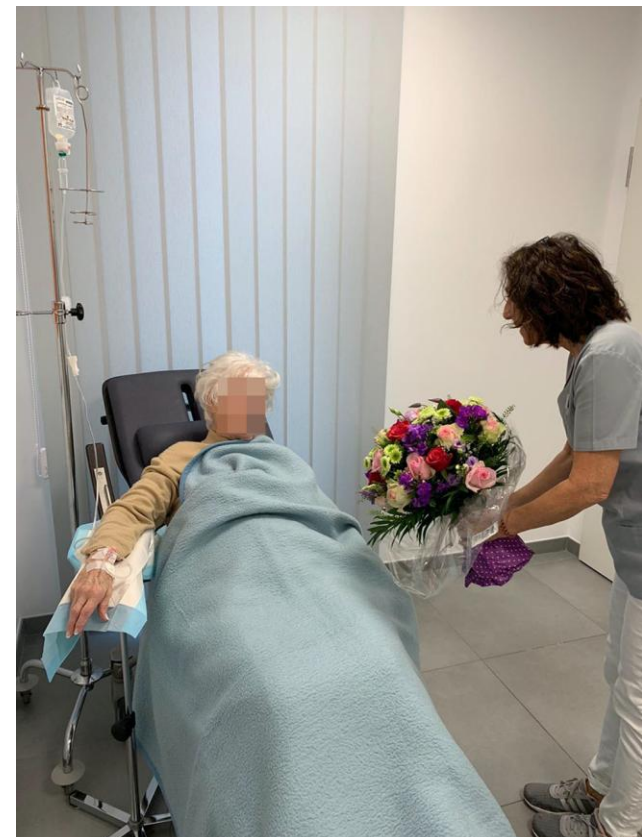Alltagsästhetik

Katja Dicke¹ · Vasileios Dervenis¹ · Axel Hauschild² · Thomas Dirschka¹

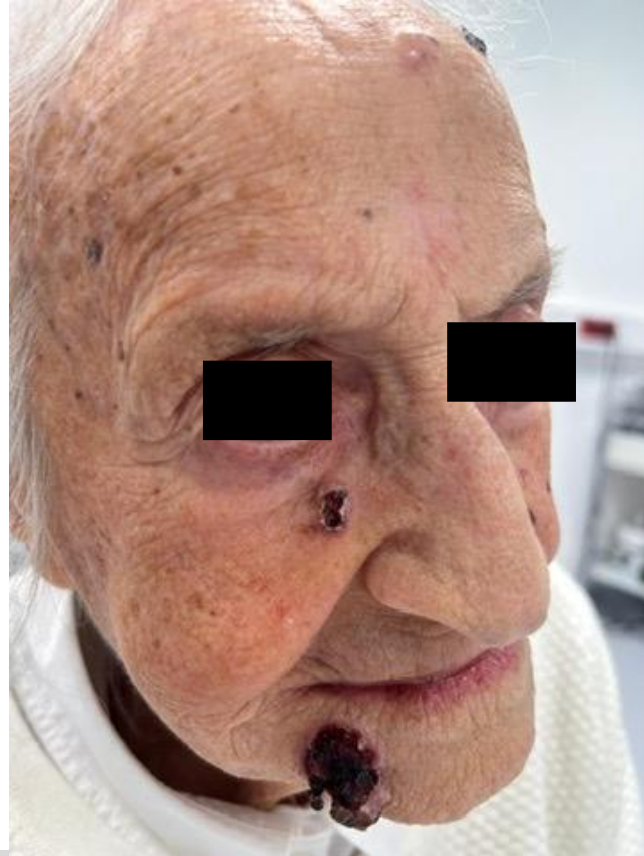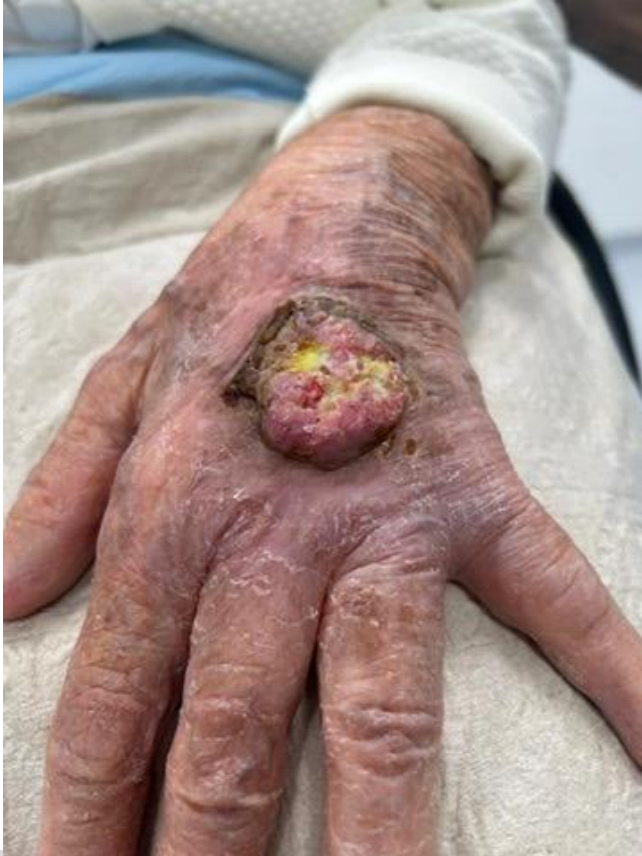¹Klinik für Dermatologie, CentroDerm GmbH, Wuppertal, Deutschland

²Klinik für Dermatologie, Venerologie und Allergologie, UKSH, Campus Kiel, Kiel, Deutschland

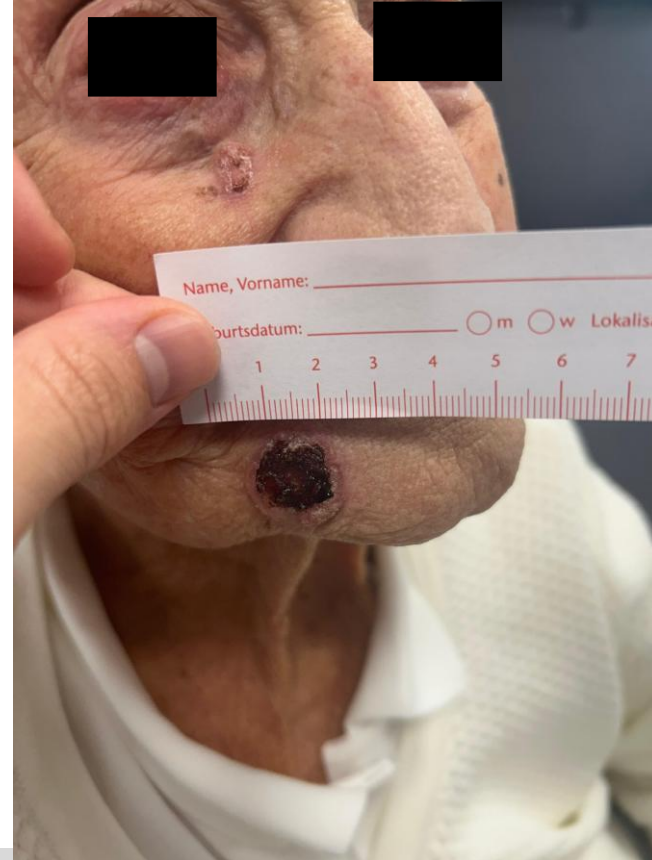
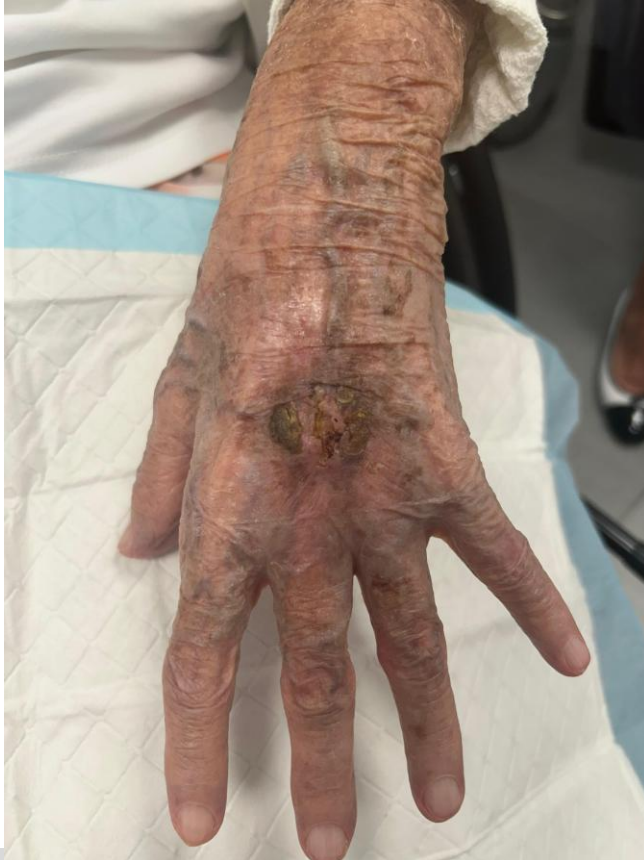Lokale Tumorkontrolle eines metastasierten Merkel-Zell-Karzinoms bei einer 90-jährigen Patientin



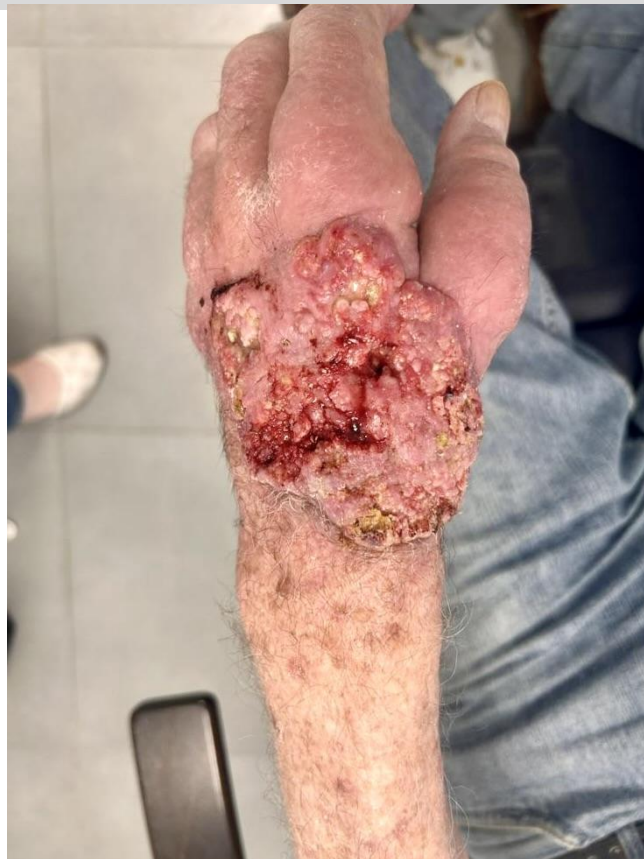95-year-old patient – What to do?



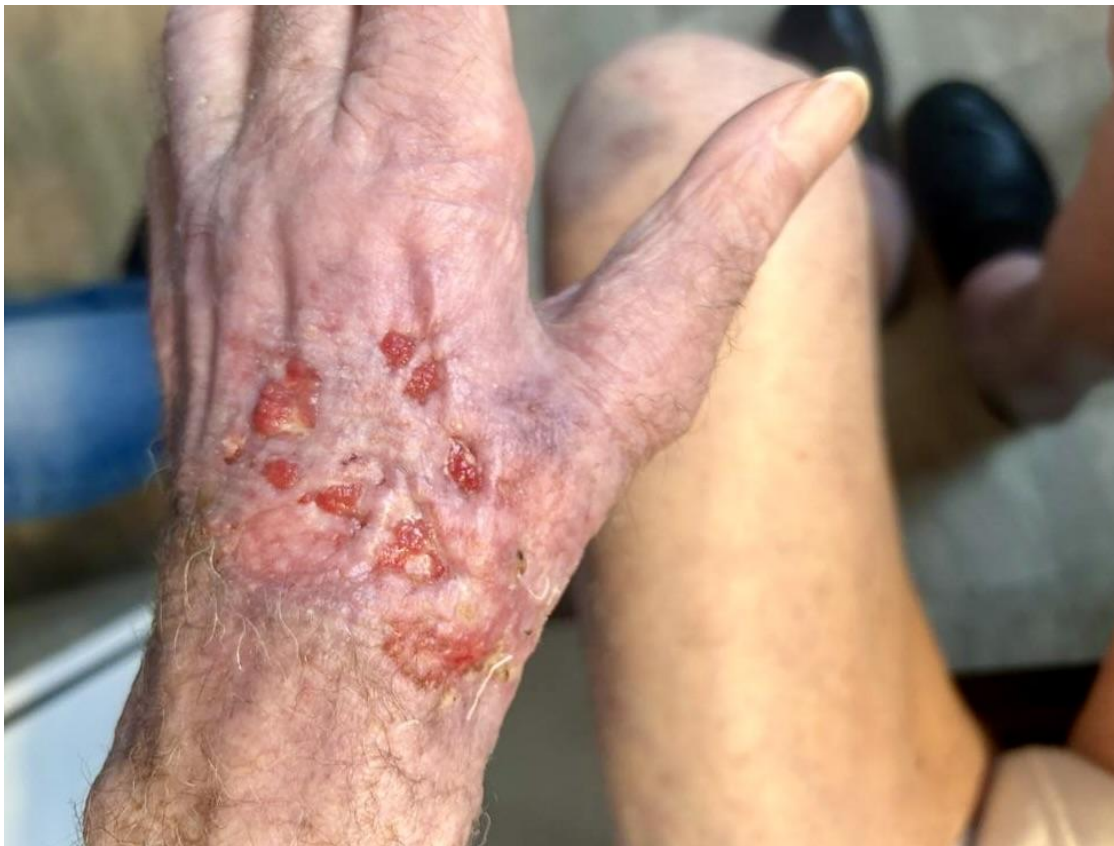PD1-antagonist Cemiplimab 3 infusions, every 3 weeks



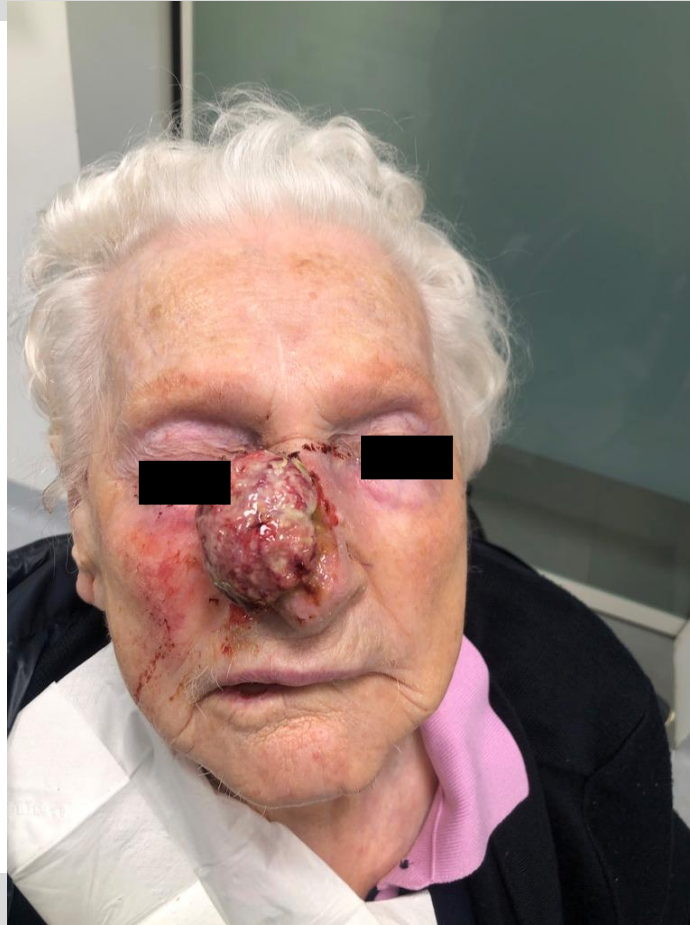89-year-old patient What to do?



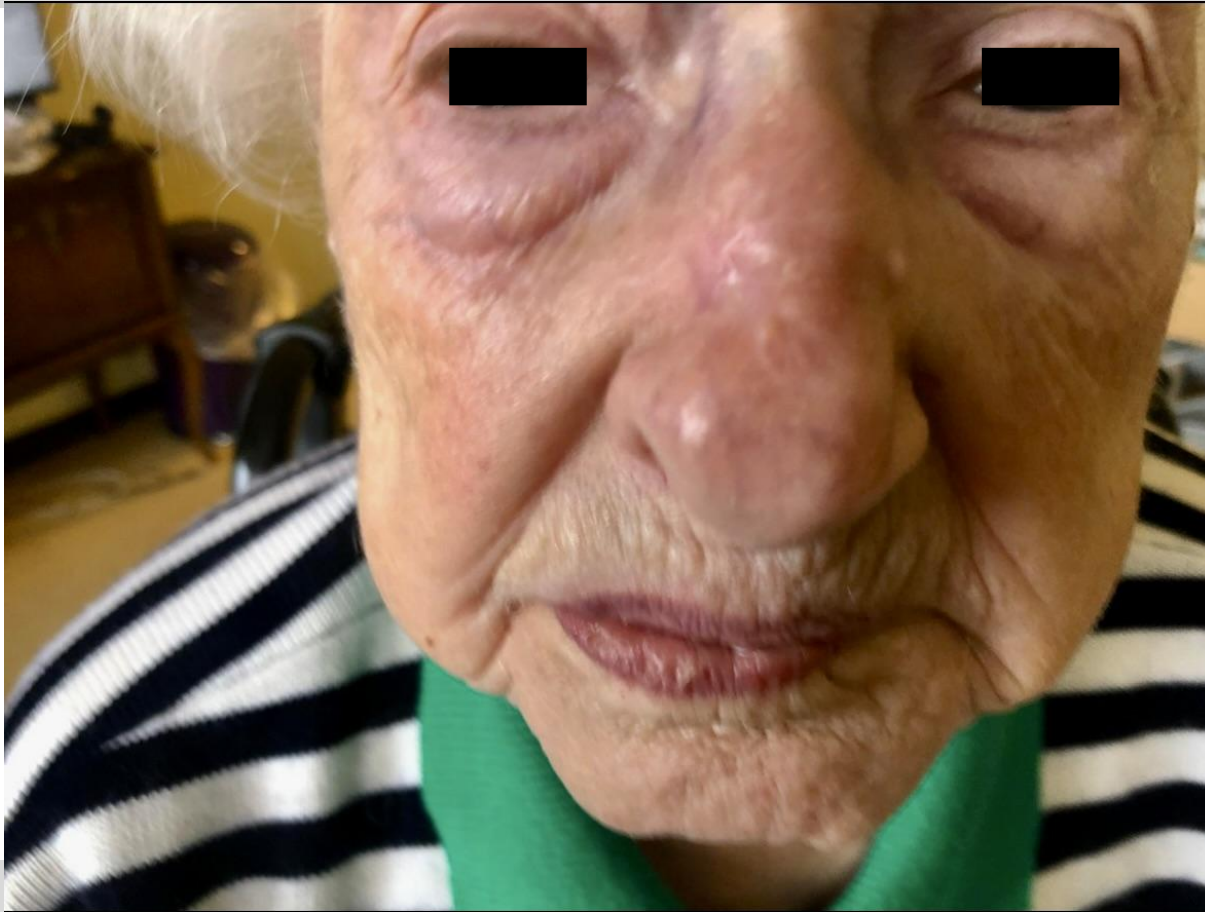PD1-antagonist Cemiplimab 3 infusions, every 3 weeks



101-year-old patient – what to do?



101-year-old patient – what to do?
→ excision of tumor and full-skin graft





Important Drug Interactions



Ingredient	Interaction with...
Itraconazole	
Terbinafine	
Isotretinoin	
Ciclosporin	
Methotrexat	



Ingredient	Interaction with...
Itraconazole	statins, Ca ²⁺ -antagonists, makrolid-antibiotics (Cyp3A4), ciclosporin, faktor-Xa-inhibitors
Terbinafine	betablockers, MAO-inhibitors, ciclosporin, tricyclic antidepressants, cimetidin
Isotretinoin	tetracycline, doxycycline (increases brain pressure), statins, fibrats (CK-elevation → often not mentioned in interaction lists)
Ciclosporin	itraconazol, terbinafin, doxycyclin, verapamil
Methotrexat	azathioprin, non-steroid antiinflammatory drugs, PPIs, Brivudin, 5-FU



Statin use:

Switch to a statin with less impact on CYP3A4

→ Pravastatin or Rosuvastatin

Fluconazole can be used if the statin dose is adjusted
(**AVOID**: Itraconazole & Ketoconazole!)

Terbinafine Therapy:

AVOID: Metoprolol & Propranolol

Consider Atenolol (1st choice, minimally dependent on CYP2D6) or Nebivolol (2nd choice, low affinity for CYP2D6)



Low-pressure system (Thrombosis, Atrial Fibrillation)

- Approximately 1 million people in Germany take oral anticoagulants (DOACs, Vitamin K antagonists)
- 225 million daily doses
- 4 million people suffer from atrial fibrillation → Care gap

High-pressure system (Heart attack & stroke prevention, stents)

- Approximately 6 million people take antiplatelet agents

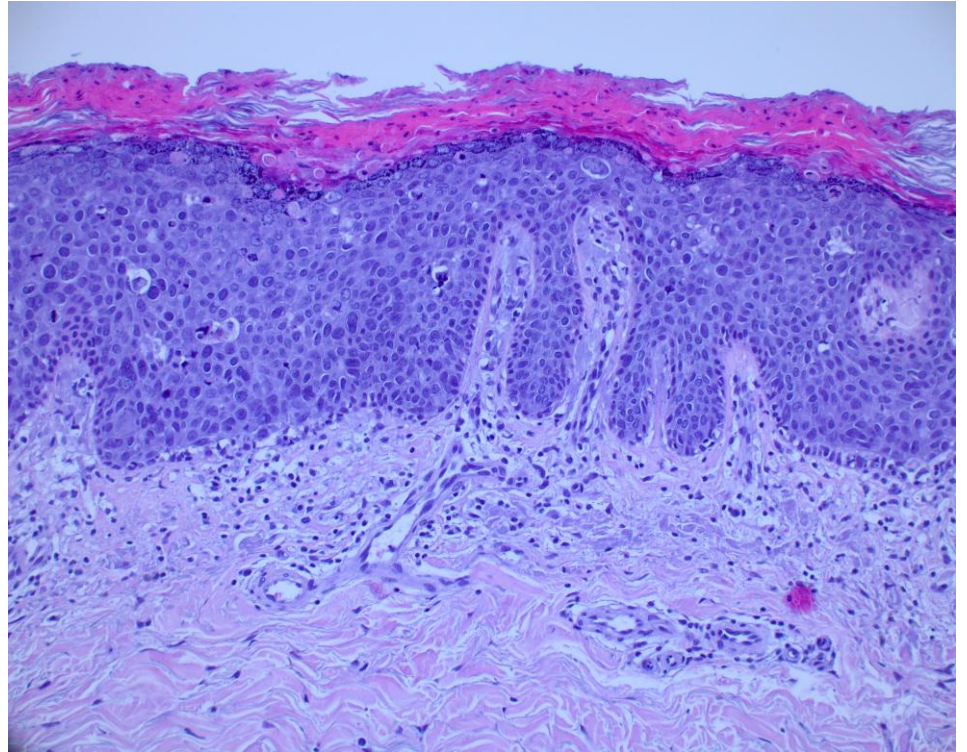
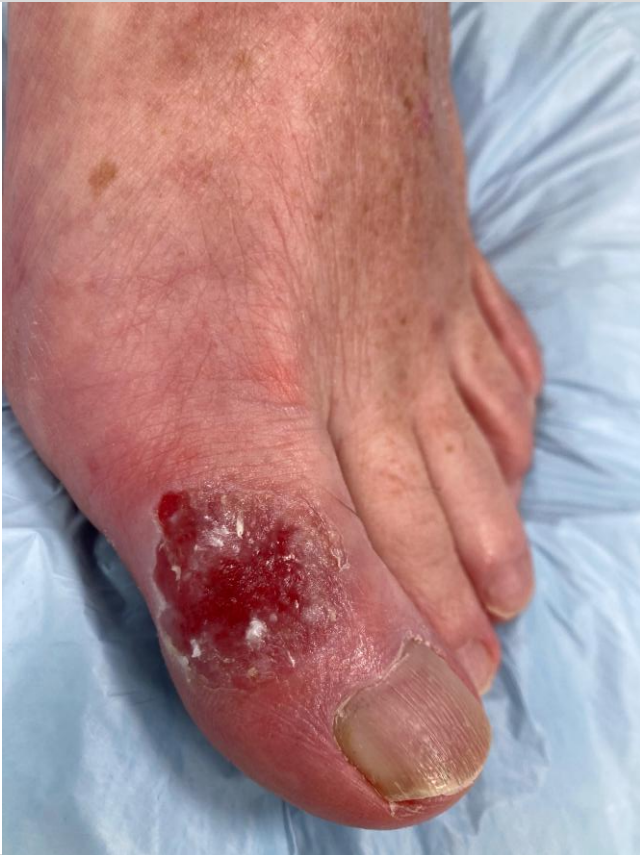

Anticoagulant	Interaction	Check
Apixaban	Itraconazole	⊖
	Terbinafine	✓
	Isotretinoin	✓
	Clindamycin	✓
Phenprocoumon	Itraconazole	⊖
	Terbinafine	✓
	Isotretinoin	✓
	Clindamycin, Cefuroxim	⊖
Clopidogrel	Itraconazole	✓
	Terbinafine	✓
	Isotretinoin	✓
	Clindamycin	✓

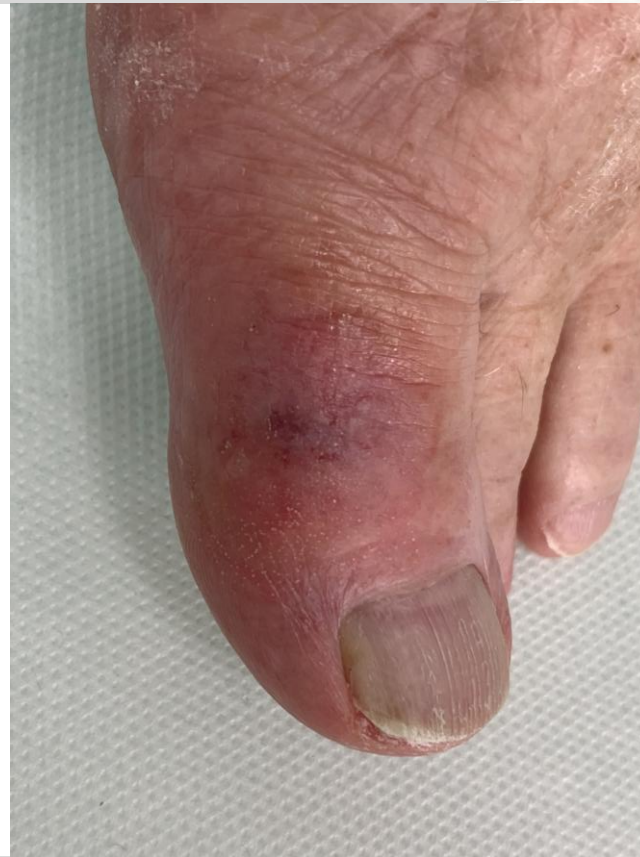
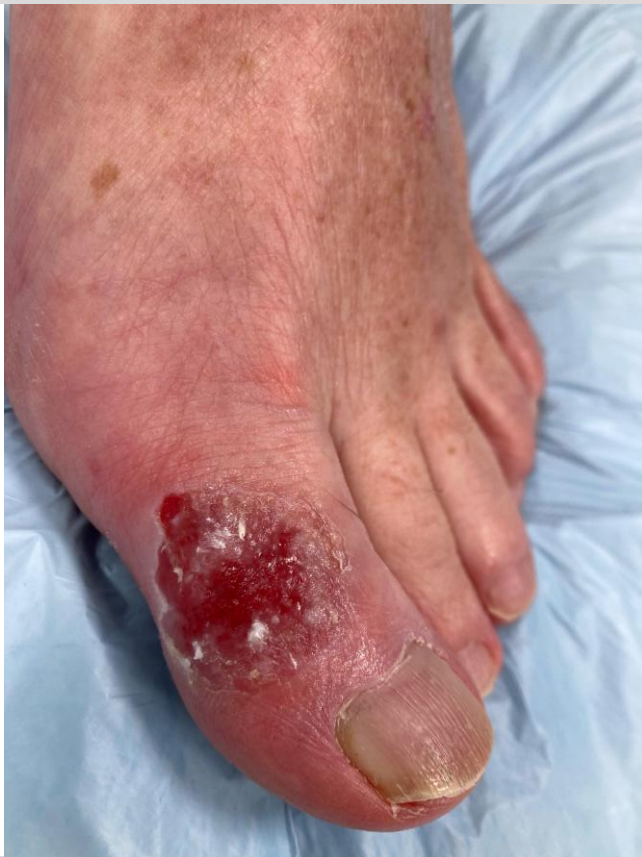
Case II

Your diagnosis? How to confirm your diagnosis? Treatment?



2 x PDT





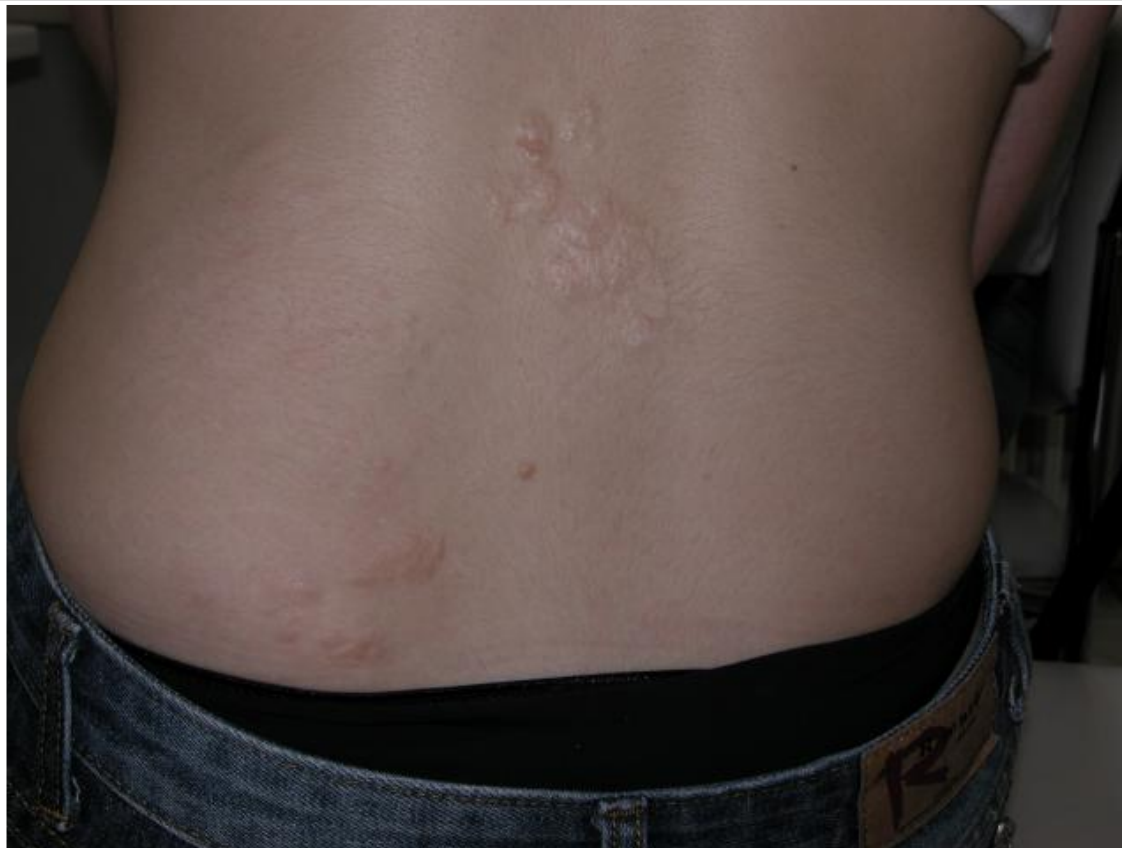Case III

Clinical finding I

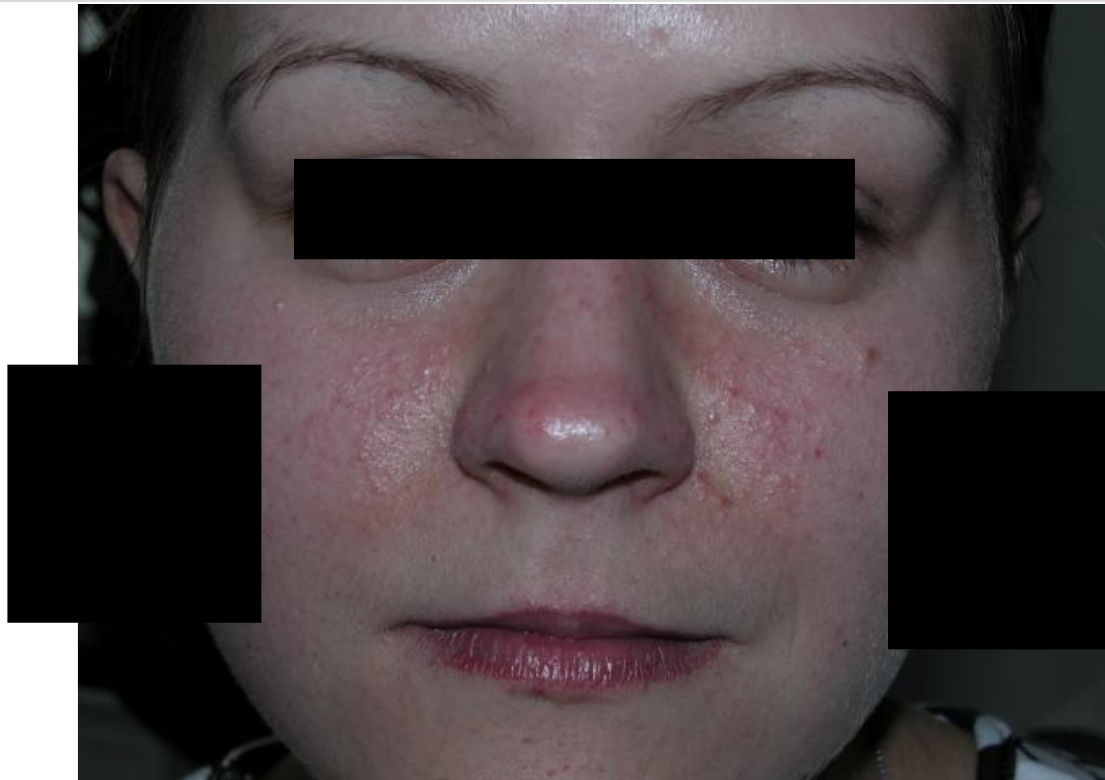

35-year-old
female patient

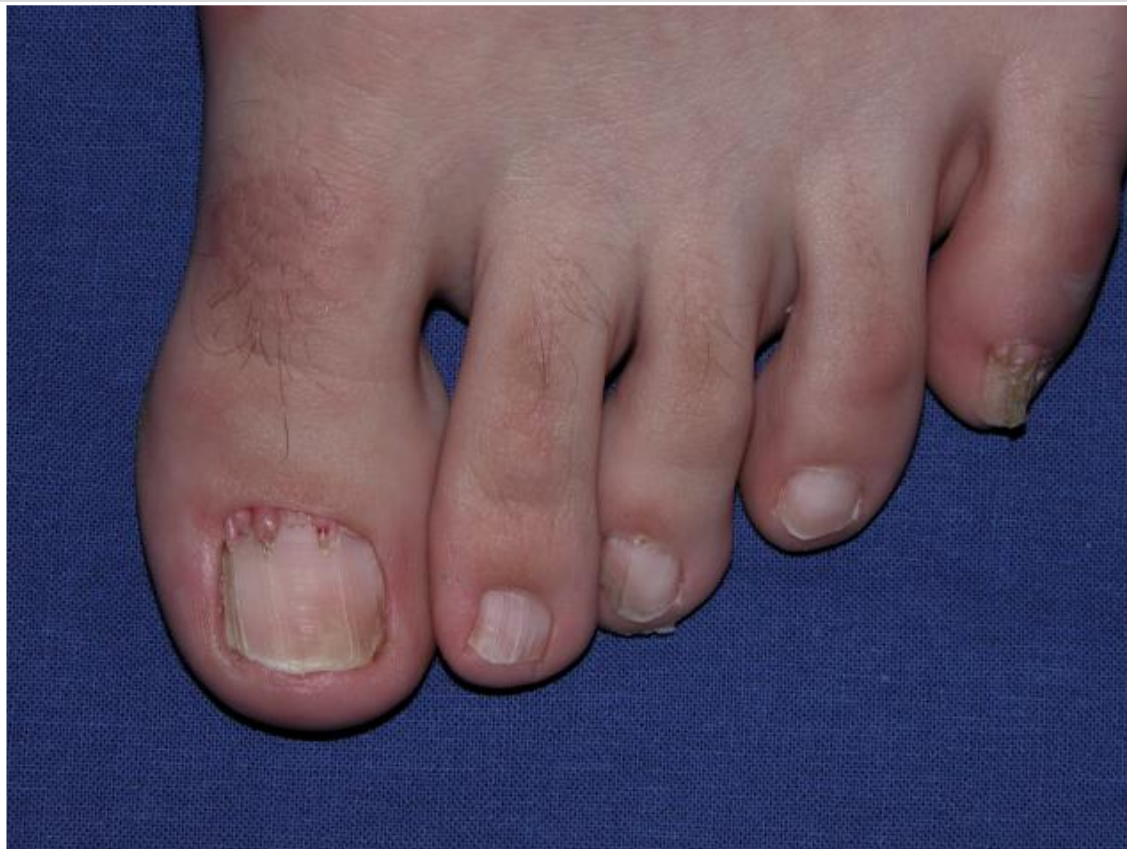since birth




Clinical finding II



Clinical finding III





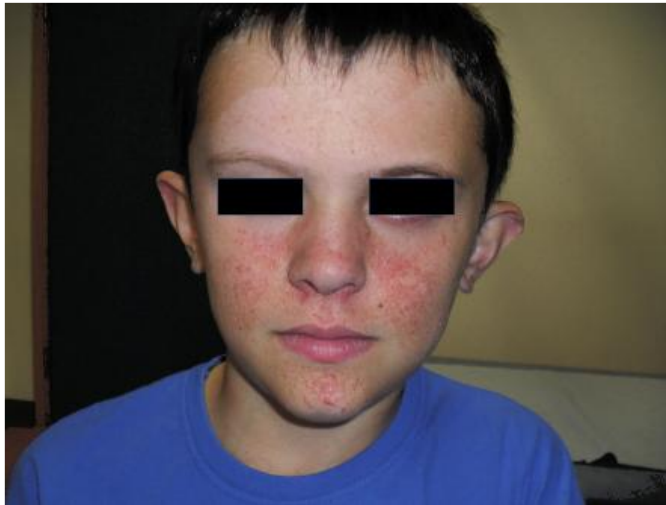Morbus Bourneville-Pringle

Autosomal-dominant

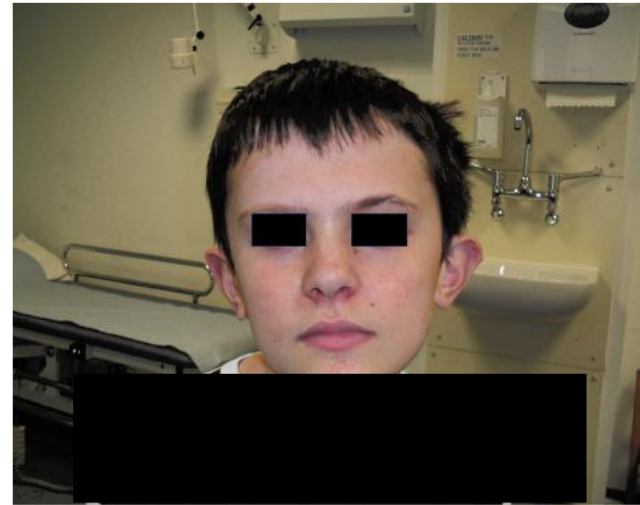50-86% new mutations

CNS-involvement! Glioneural hamartomas

Adenoma sebaceum Treatment with Sirolimus Salbe




(a) Before treatment

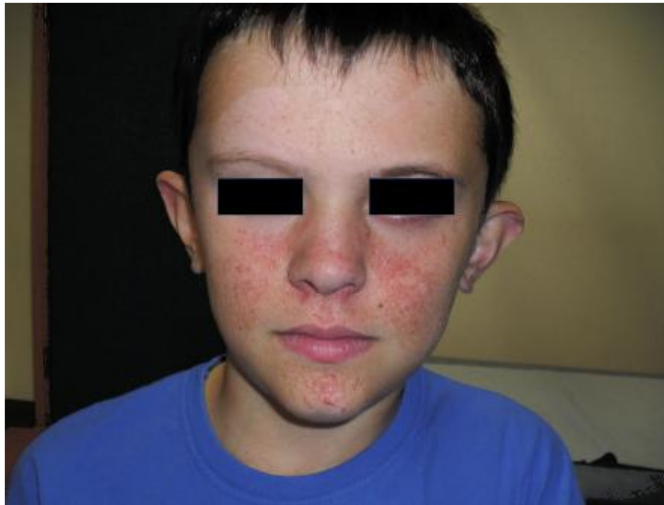

(b) After treatment

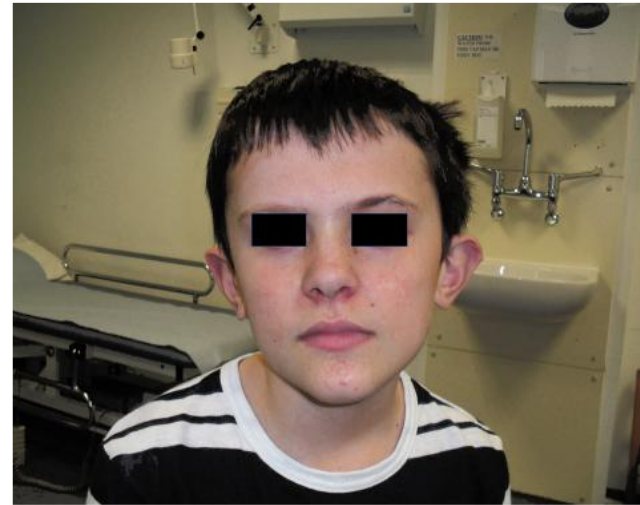Adenoma sebaceum Treatment with Sirolimus Salbe



Mutation of TSC 1 or 2 genes lead to overexpression of mTOR
Sirolimus: mTOR inhibitor → angiofibromas and inflammation are reduced



(a) Before treatment

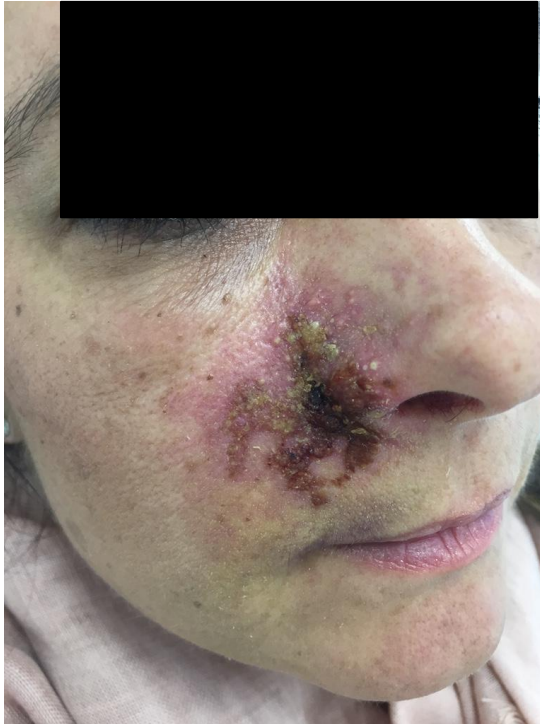


(b) After treatment



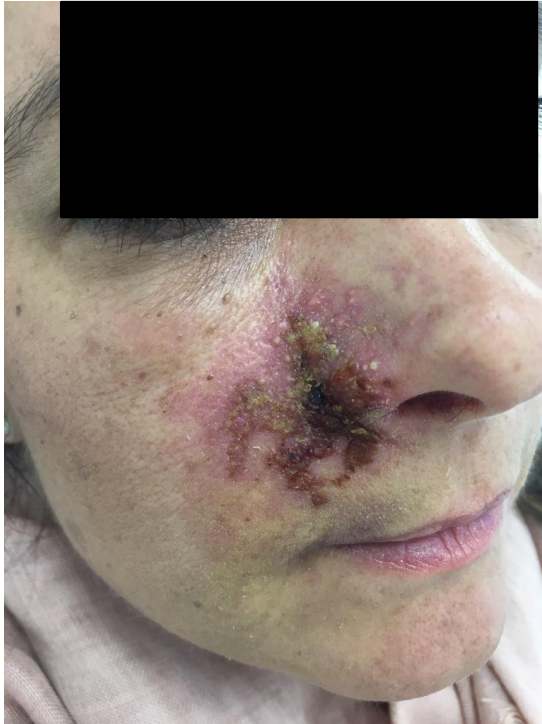Case IV

What has happened?



35-year-old women
Progressive skin change since 12
hours
painful

What has happened?

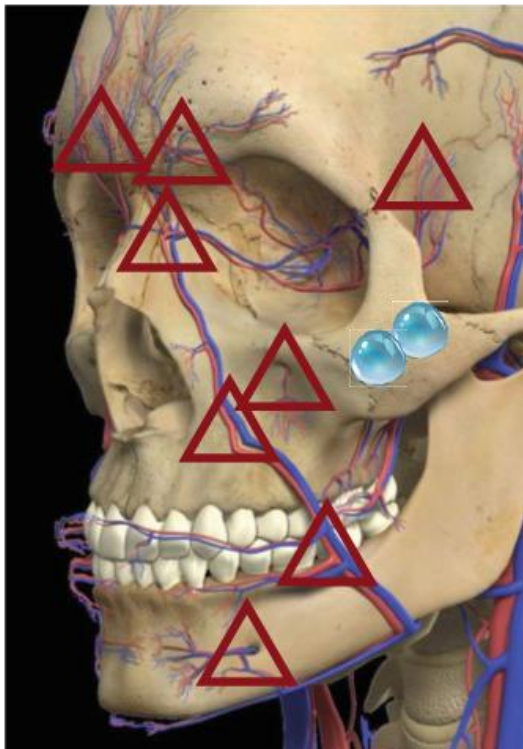


History:

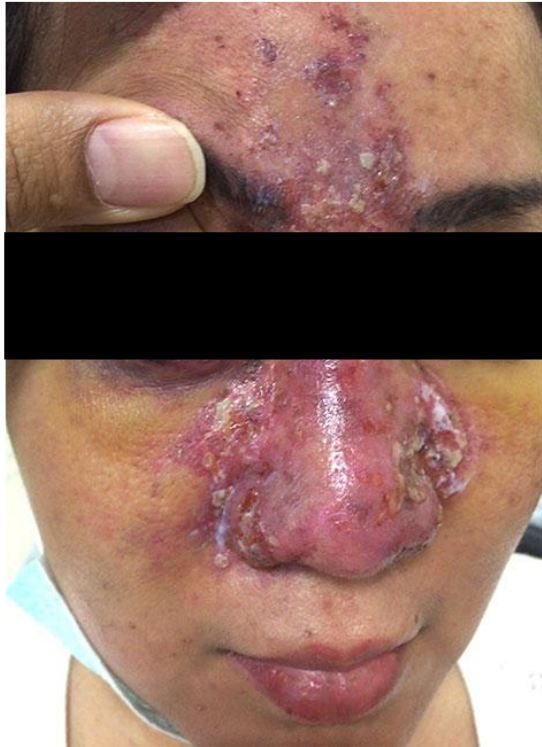injection of hyaluronic acid

Injection site: nasolabial fold

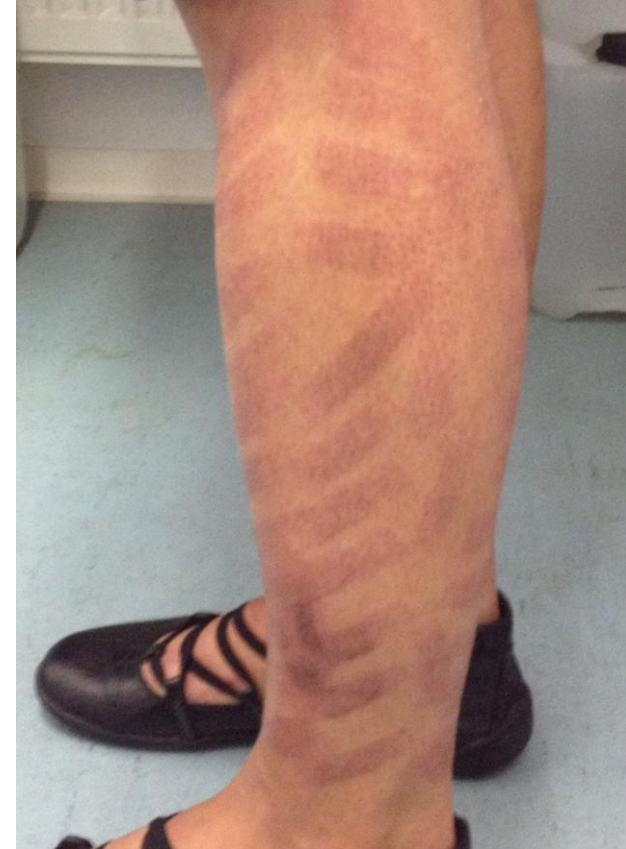Riskful sites for HA injections



Amaurosis following HA injection



What is this

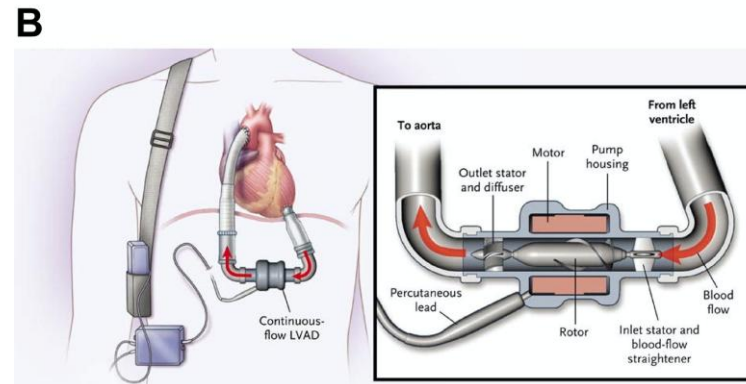
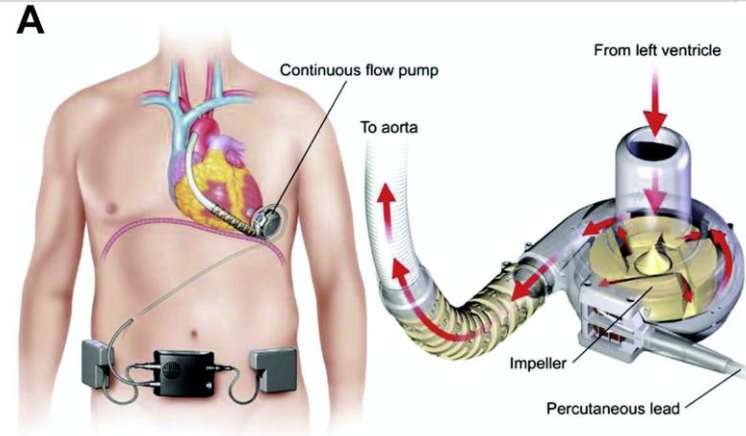
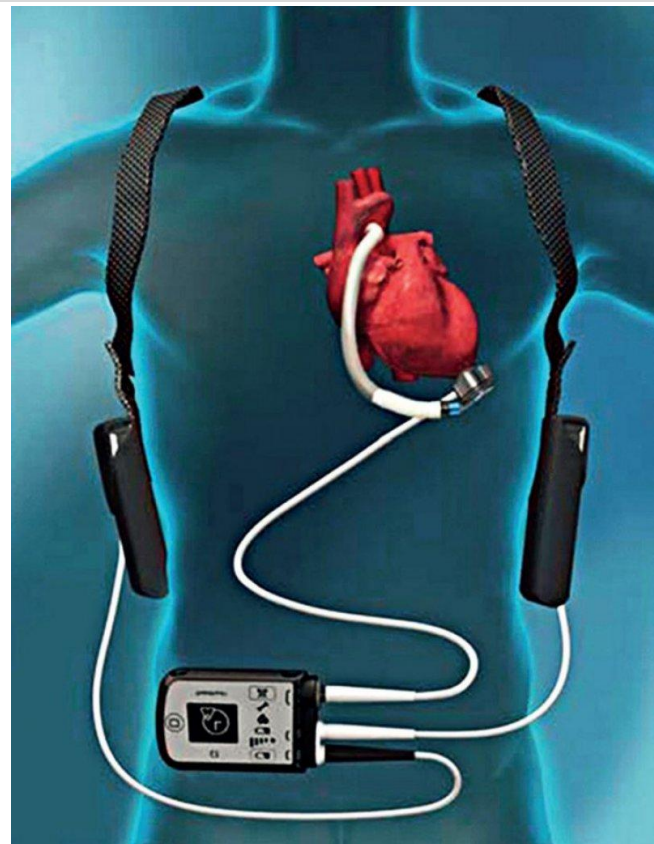


Application of an Intense Pulsed Light (IPL) flash
lamp for hair removal
Post-treatment hyperpigmentation



Case V

LVAD



Quelle: Abbott


Source: AJKD-Blog



77-year-old male patient

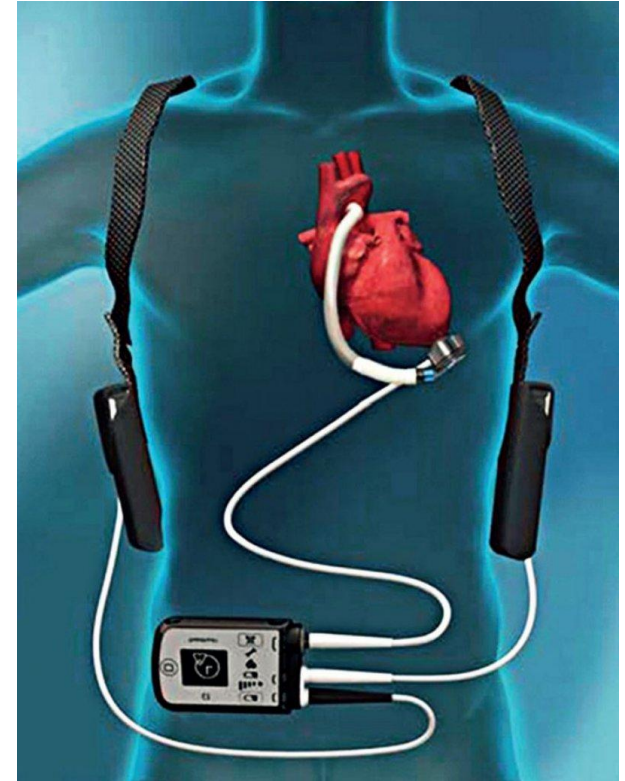
Since 2019 LVAD („Left Ventricular Assist Device“)

„Destination Therapy“



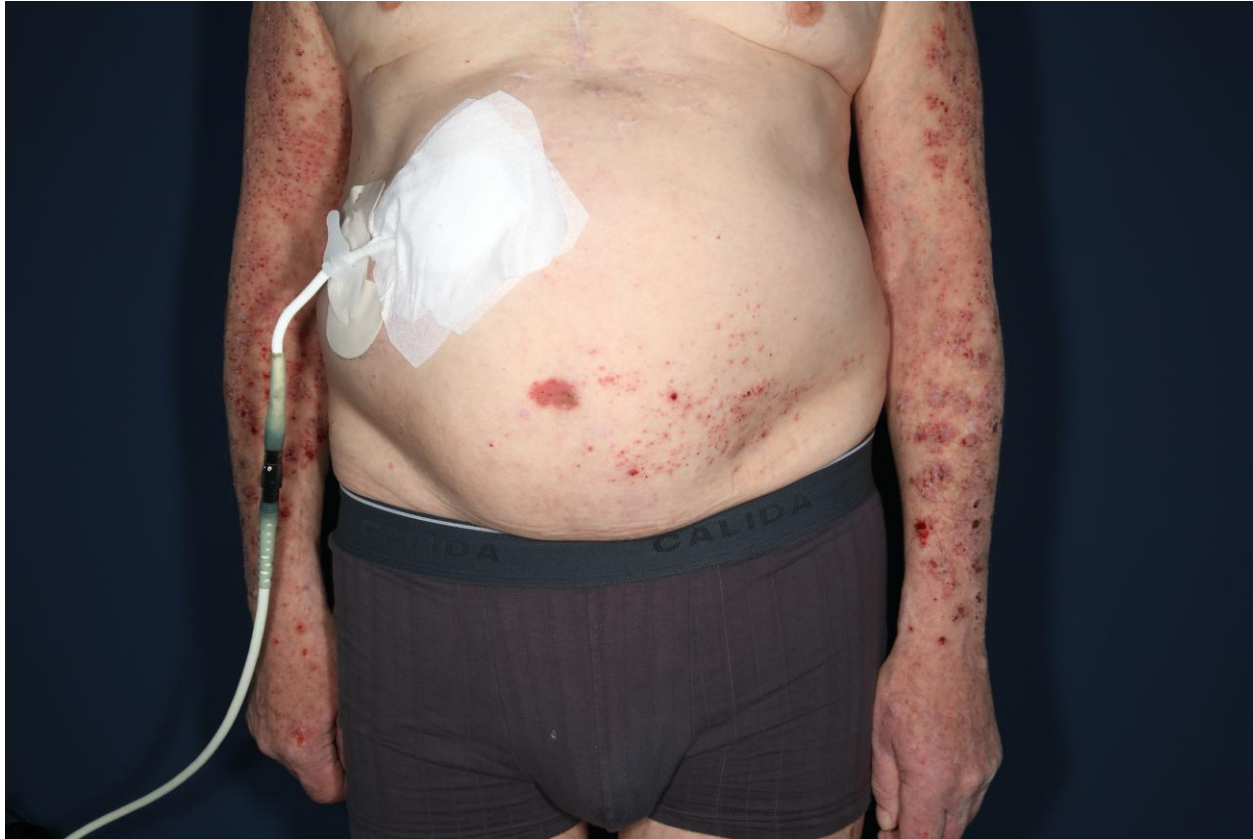Problem: Infection of driveline

Sepsis rate: 15-20% per patient per year



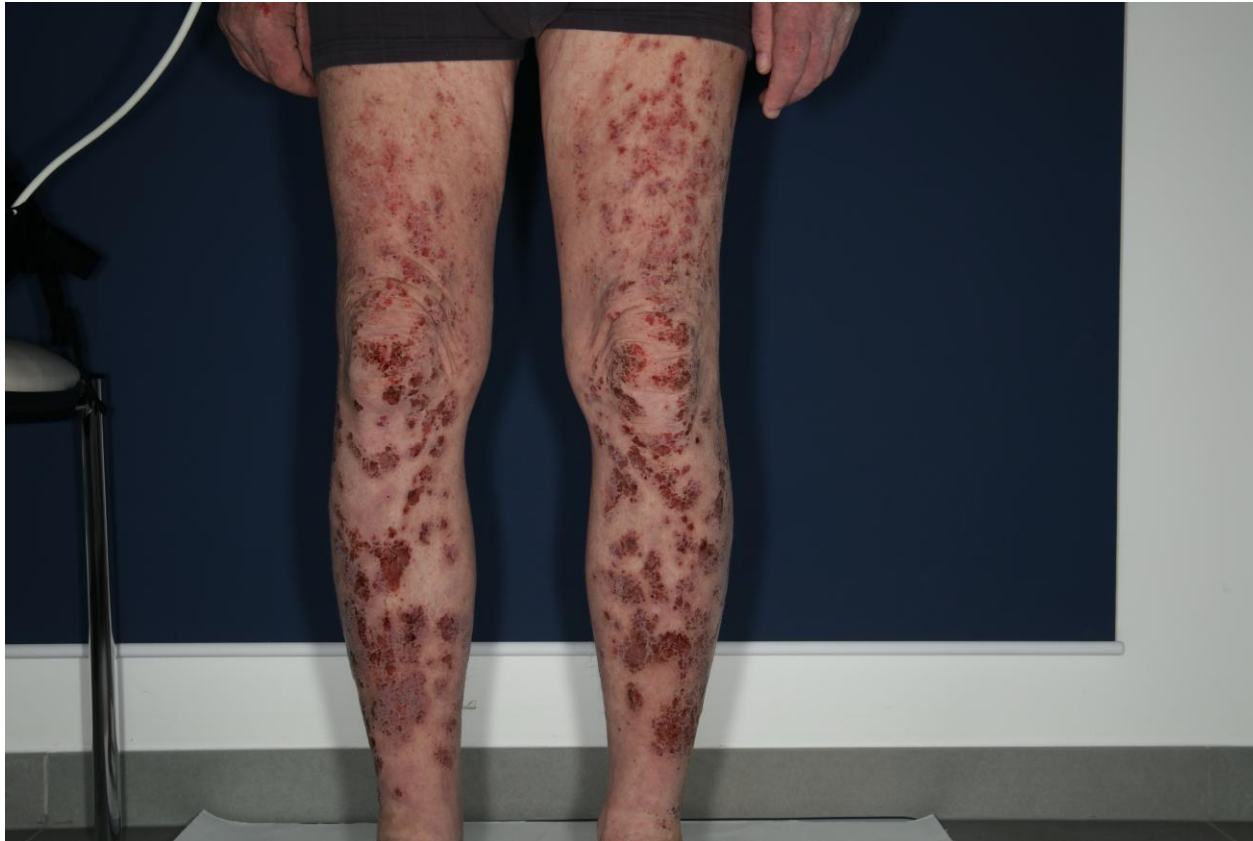Source: Abbott

September 2021



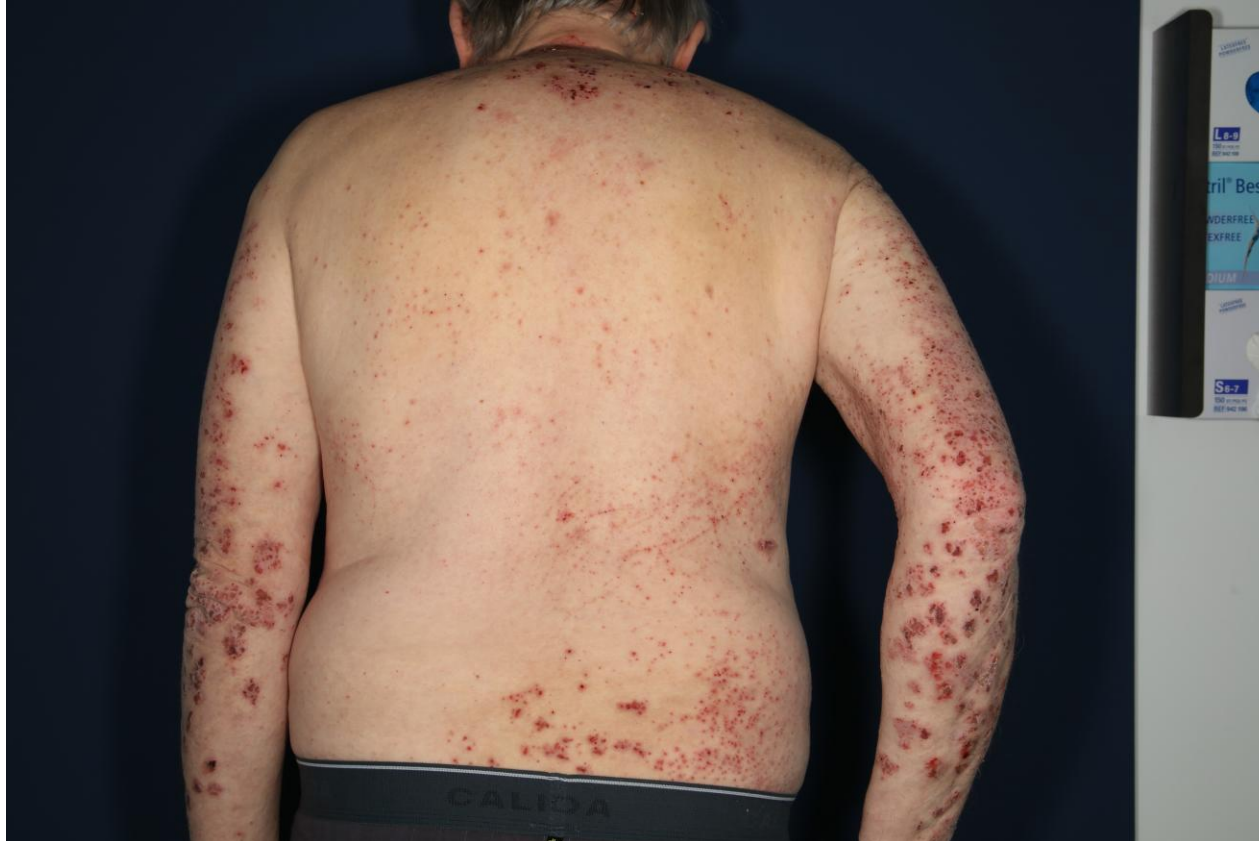Source:
Thomas Dirschka

September 2021



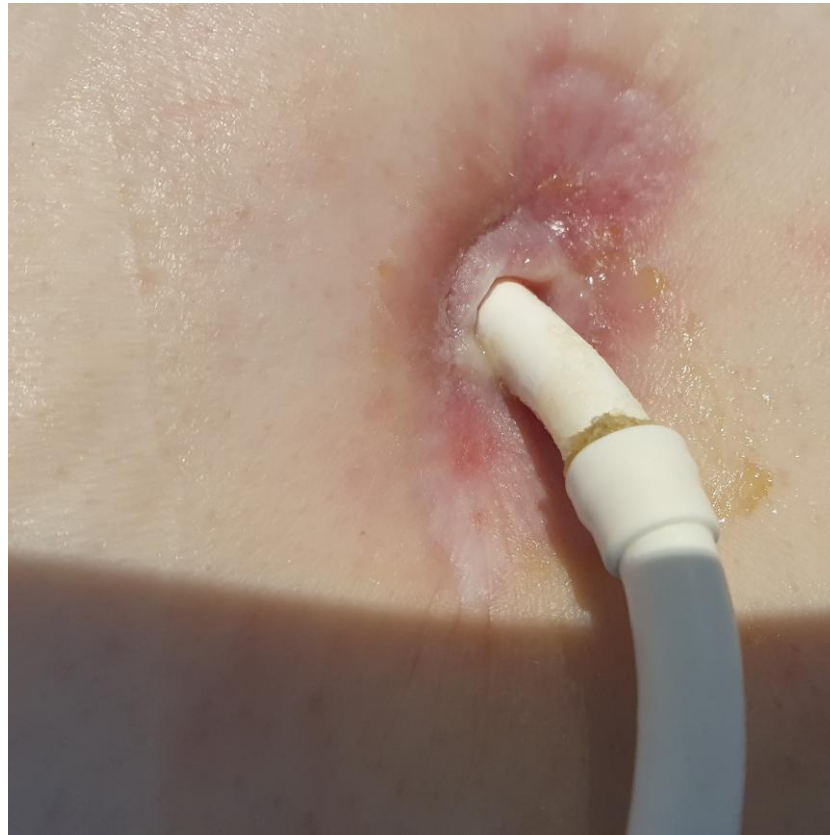Source:
Thomas Dirschka

September 2021



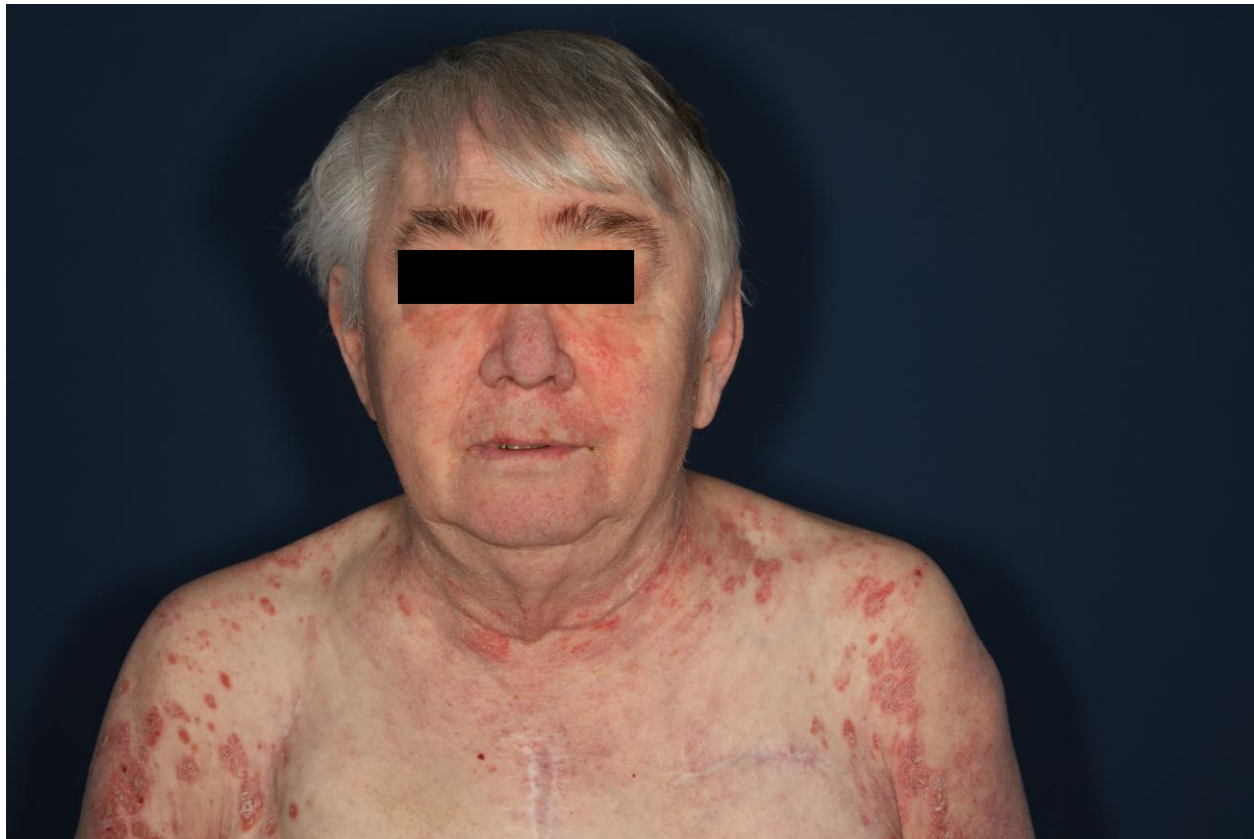Source:
Thomas Dirschka

Infection of driveline, September 2021



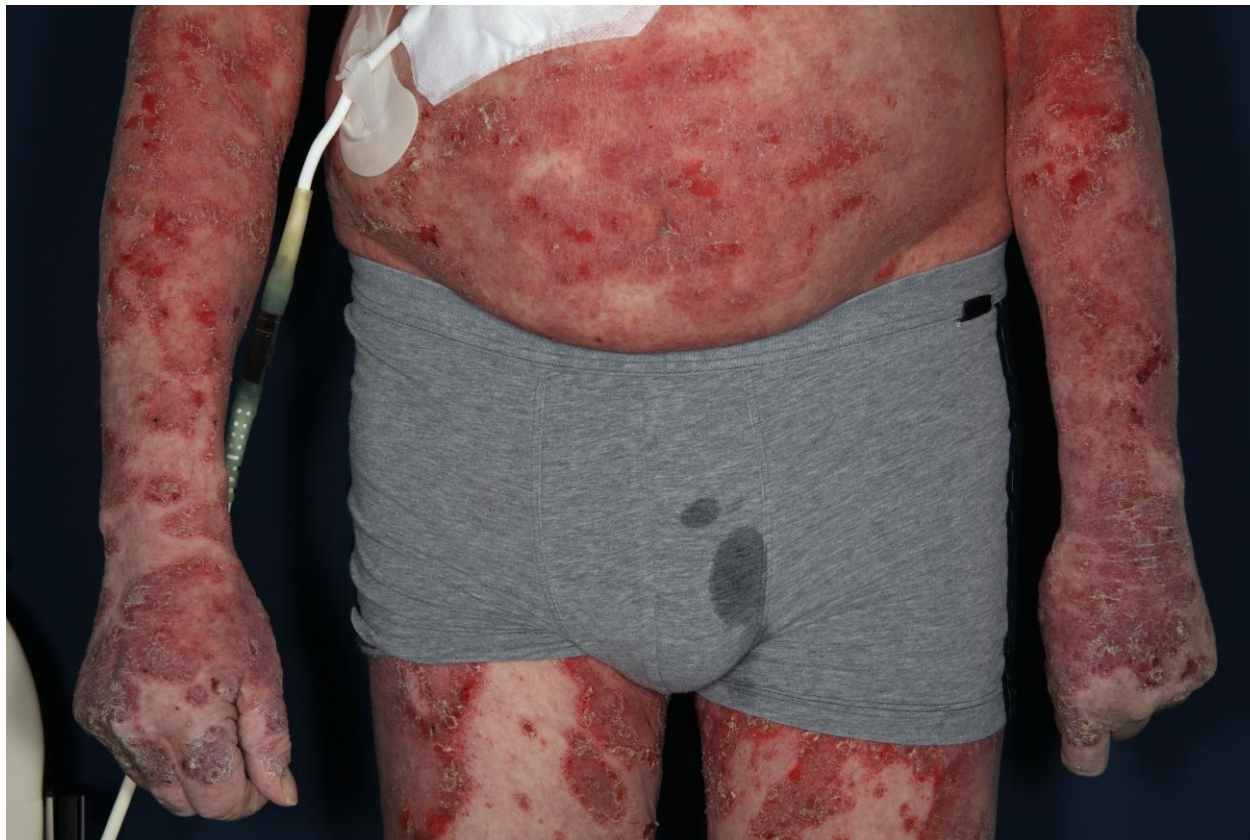Source:
Thomas Dirschka

December 2021



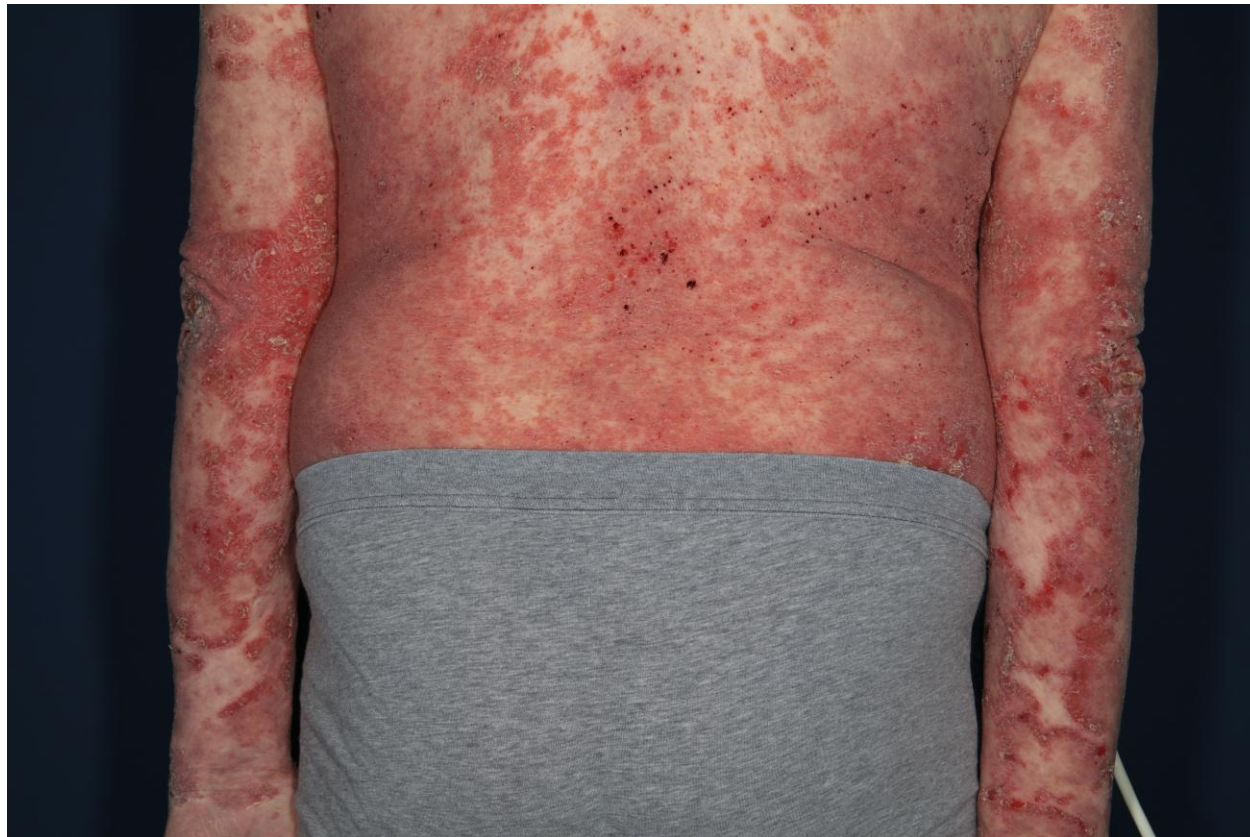Source:
Thomas Dirschka

December 2021



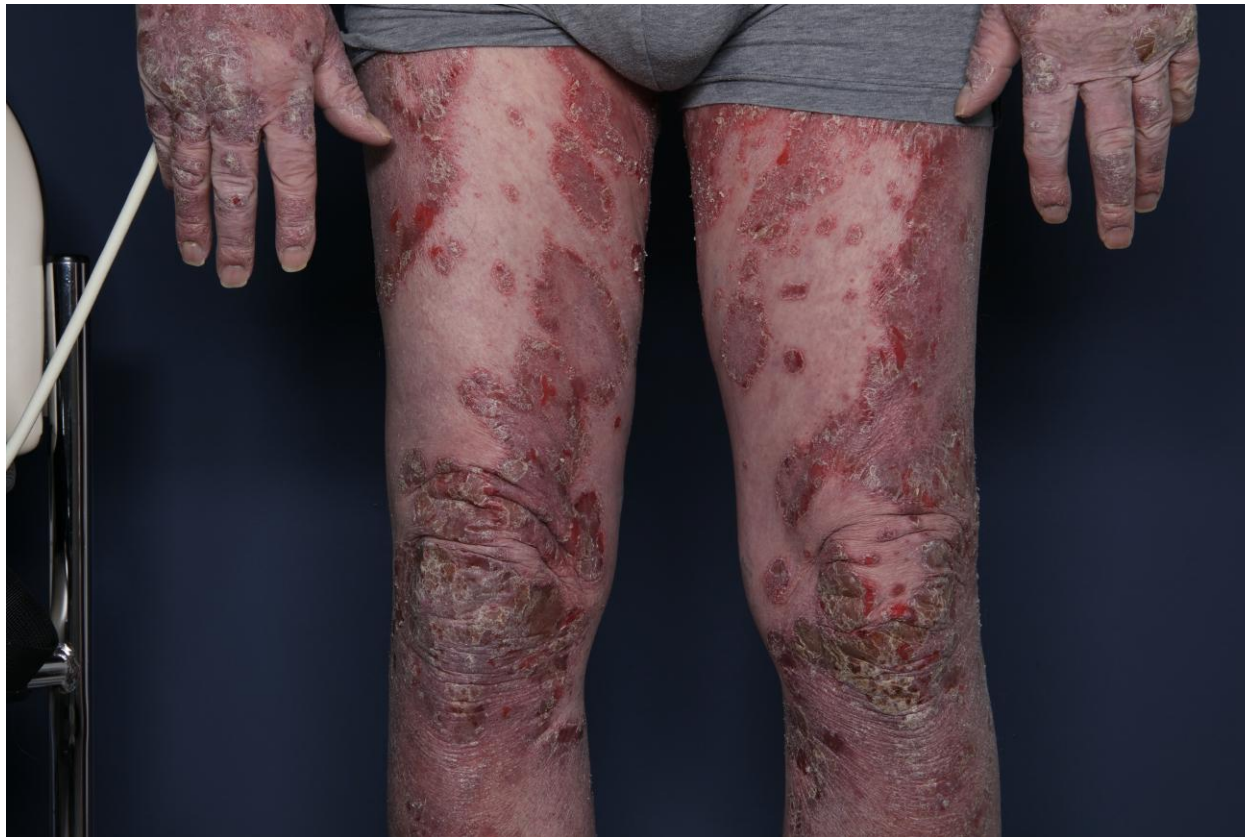Source:
Thomas Dirschka

December 2021



Source:
Thomas Dirschka

December 2021



Source:
Thomas Dirschka



18.12.2021 Start Bimekizumab

03.01.2022 Presentation at CentroDerm



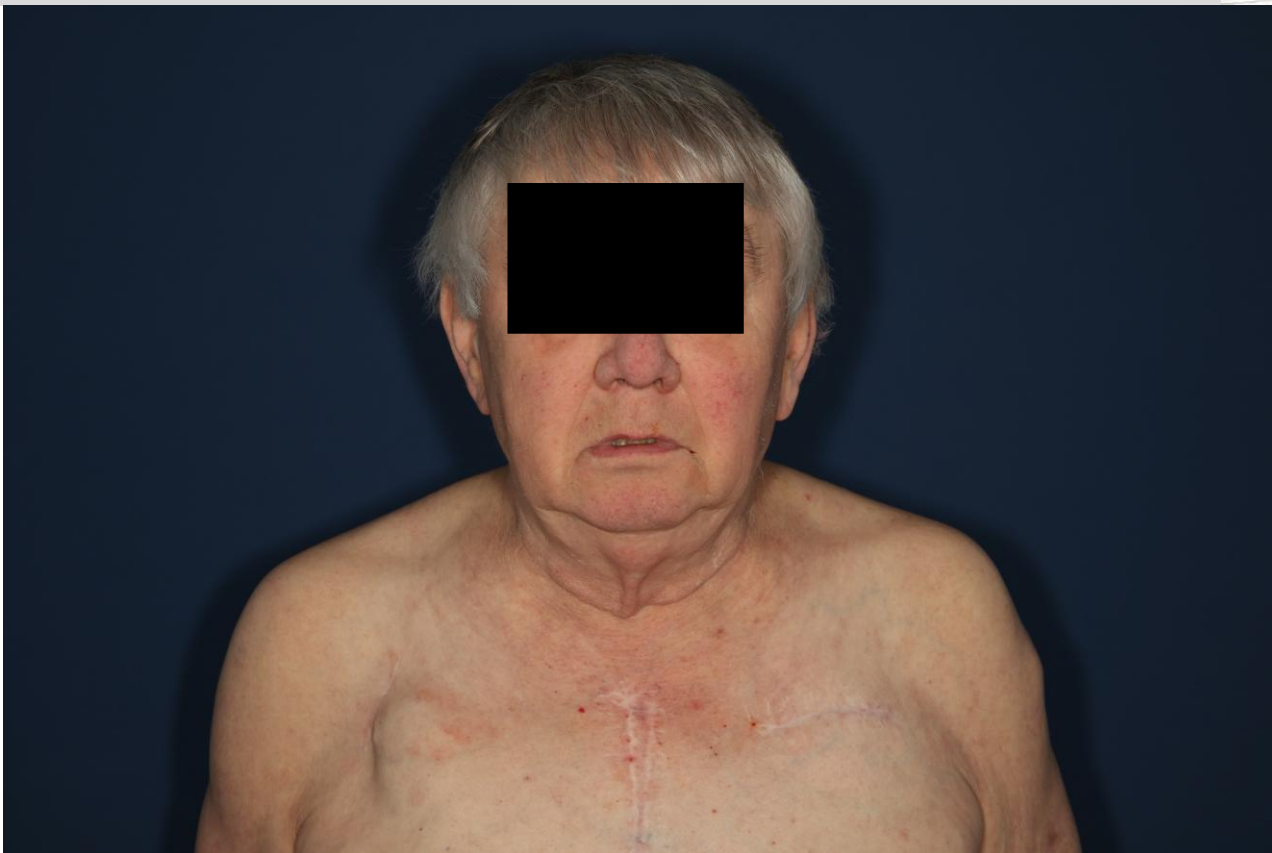
18.12.2021:

PASI 46,8

BSA 40%

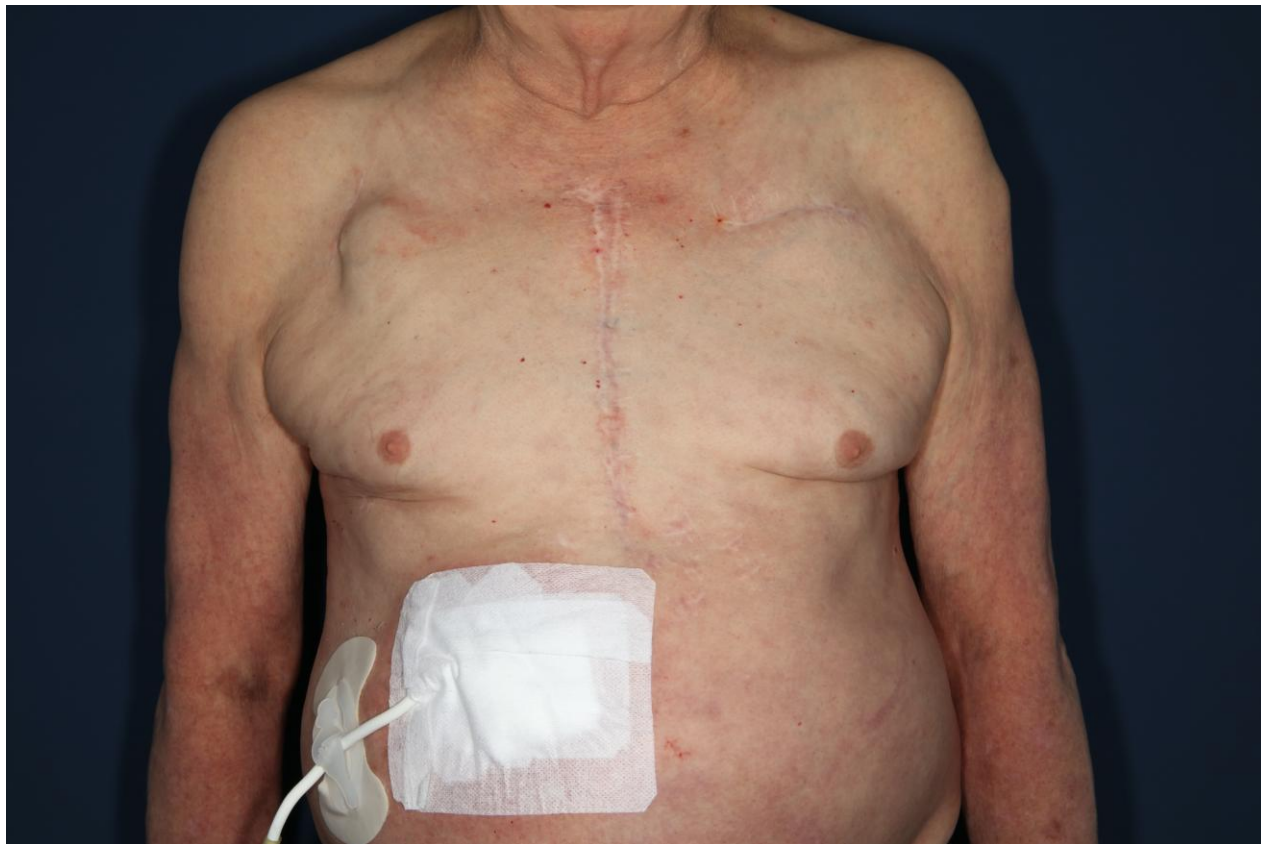DLQI 23

03.01.2022



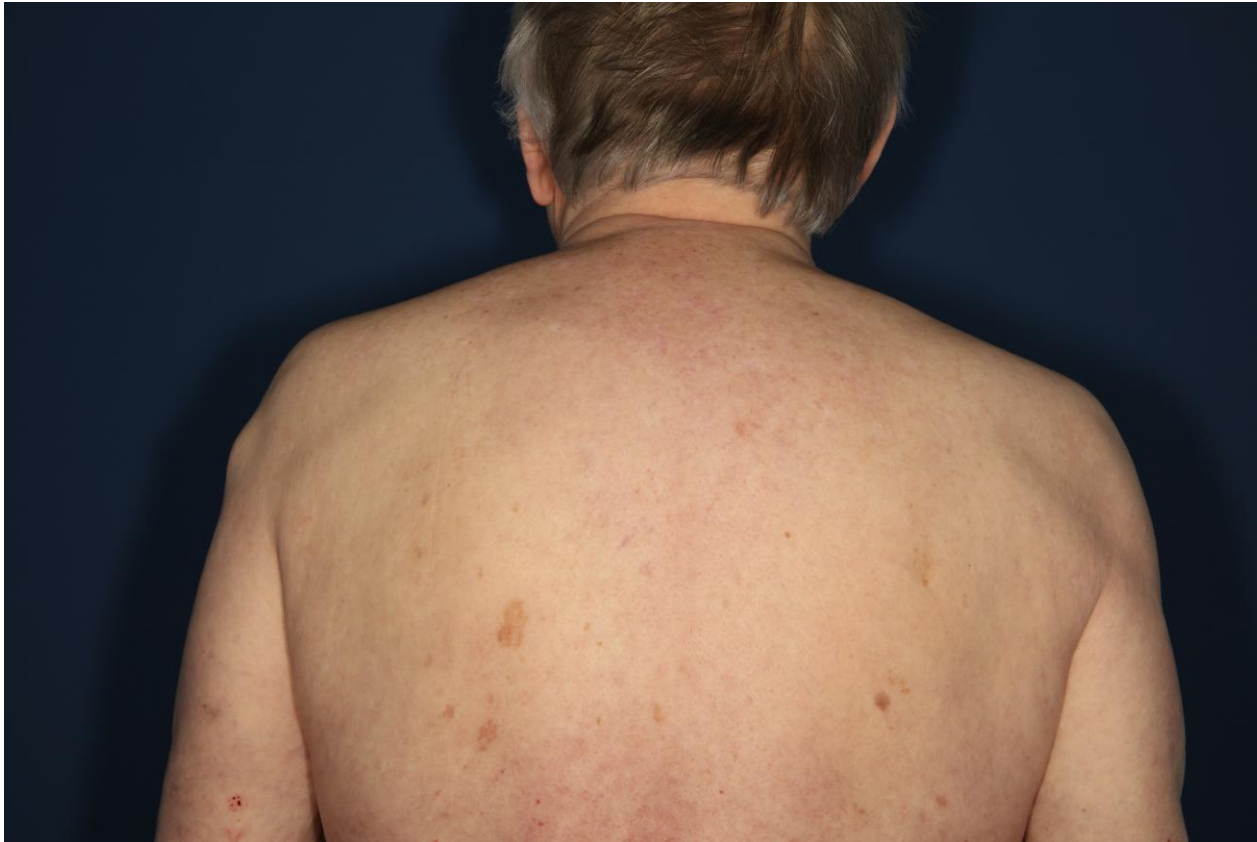Source:
Thomas Dirschka

03.01.2022



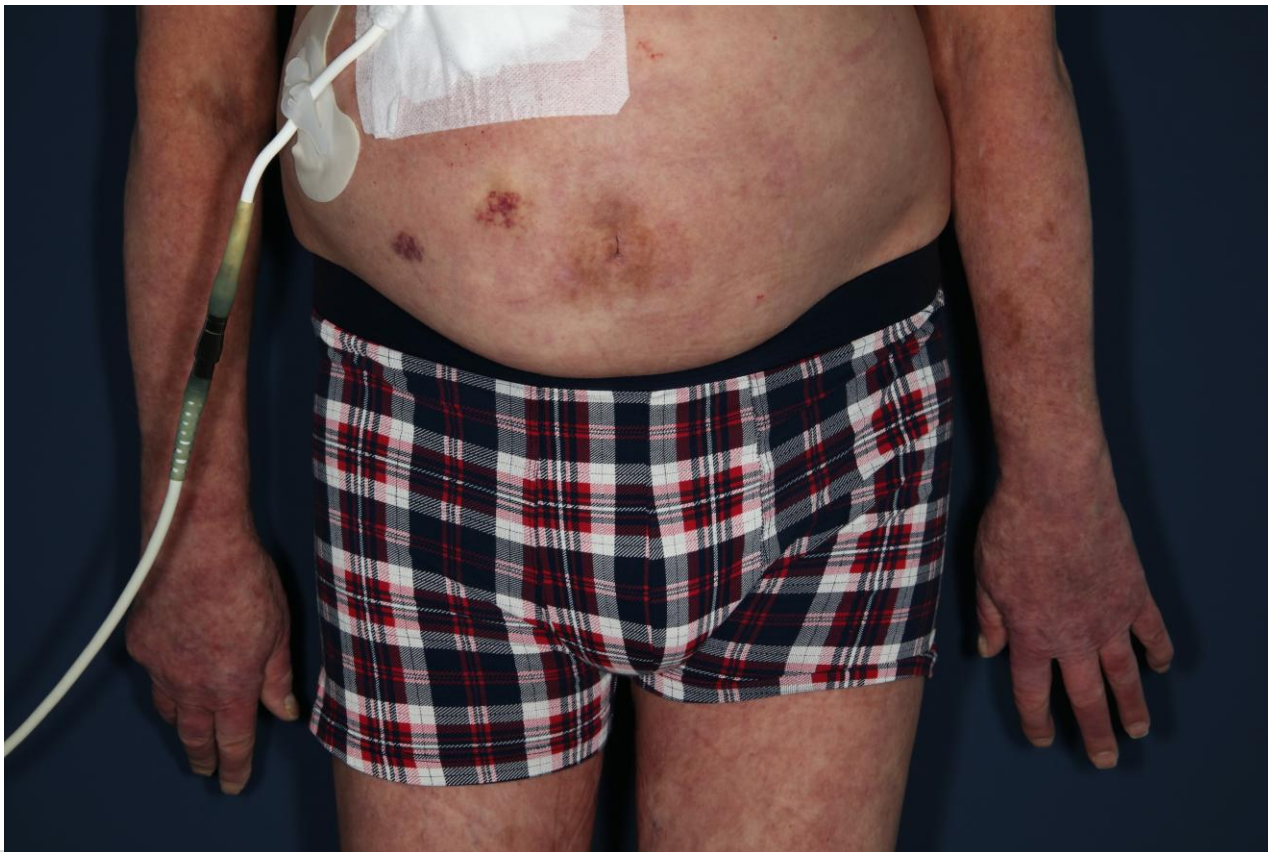
Source:
Thomas Dirschka

03.01.2022



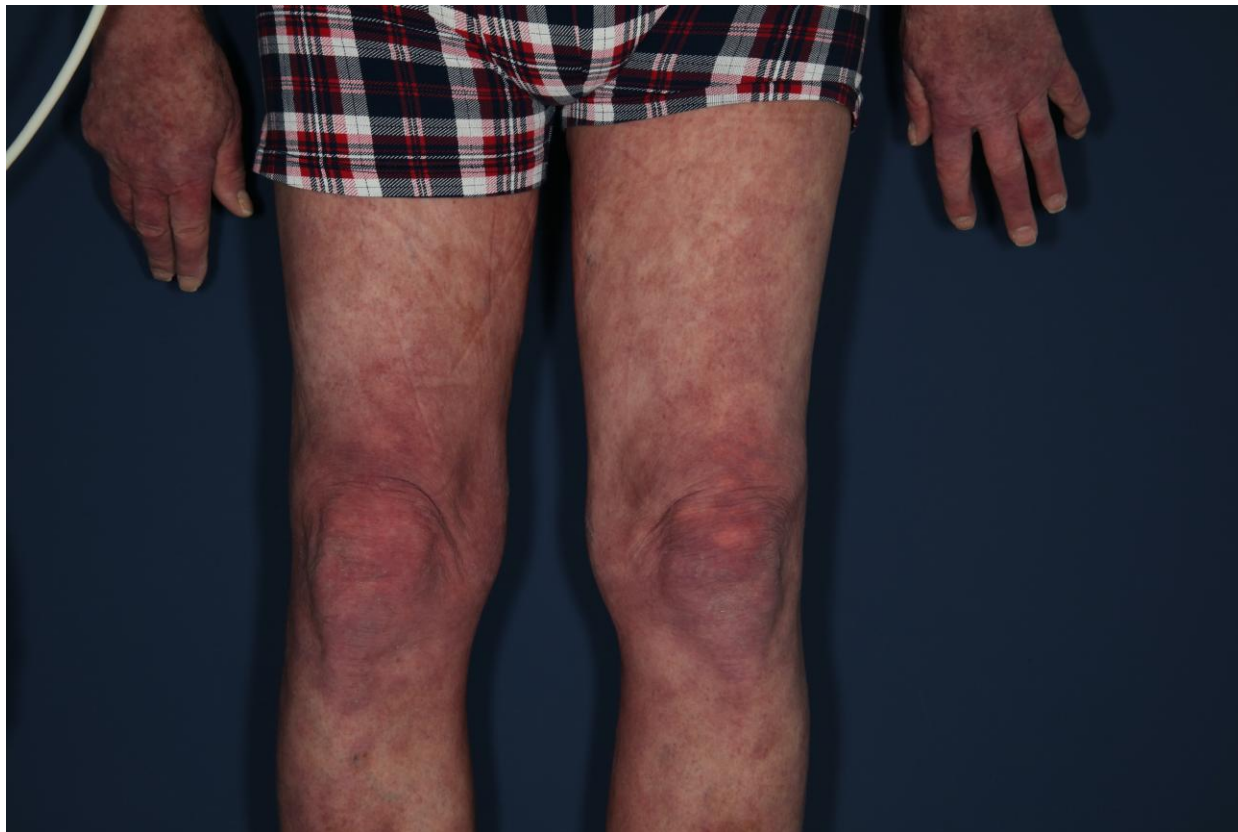Source:
Thomas Dirschka

03.01.2022



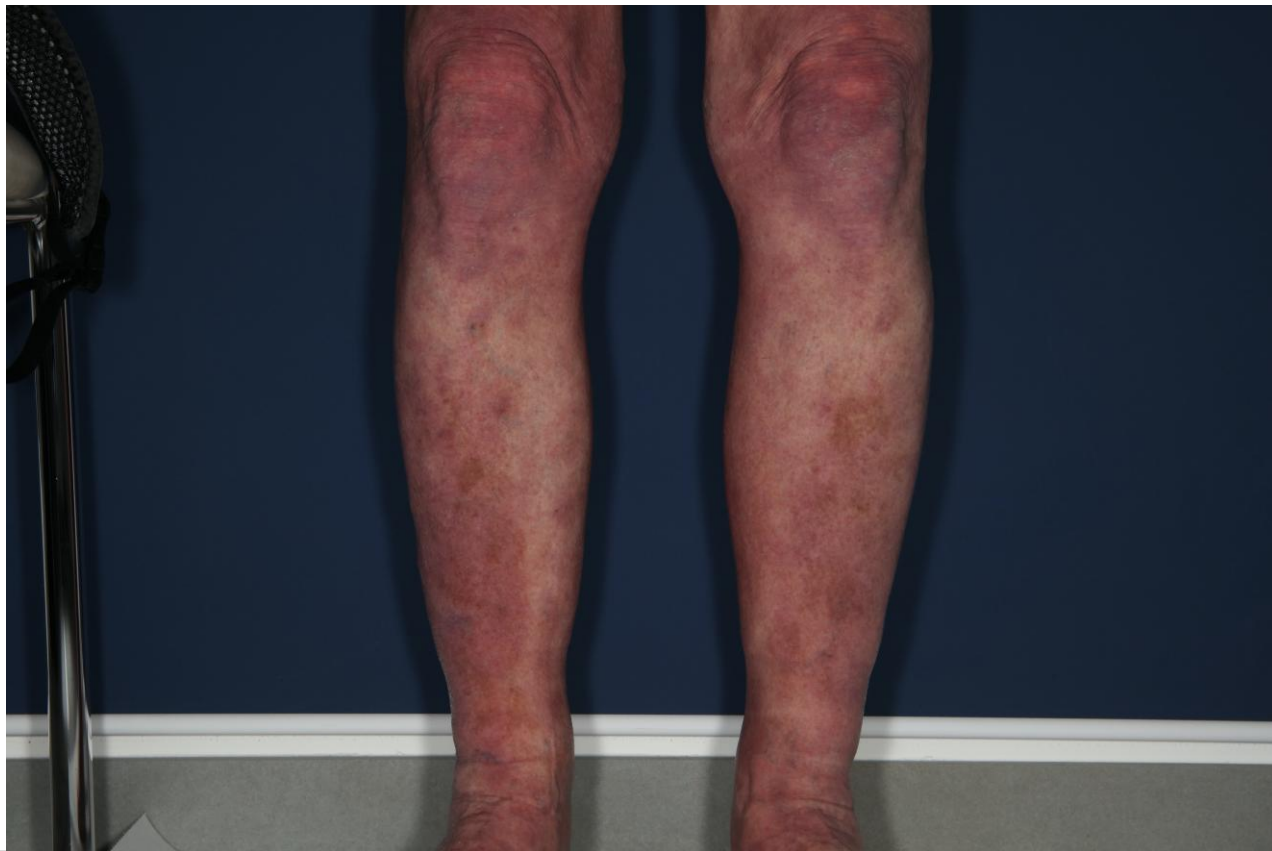Source:
Thomas Dirschka

03.01.2022




Source:
Thomas Dirschka

03.01.2022



Source:
Thomas Dirschka

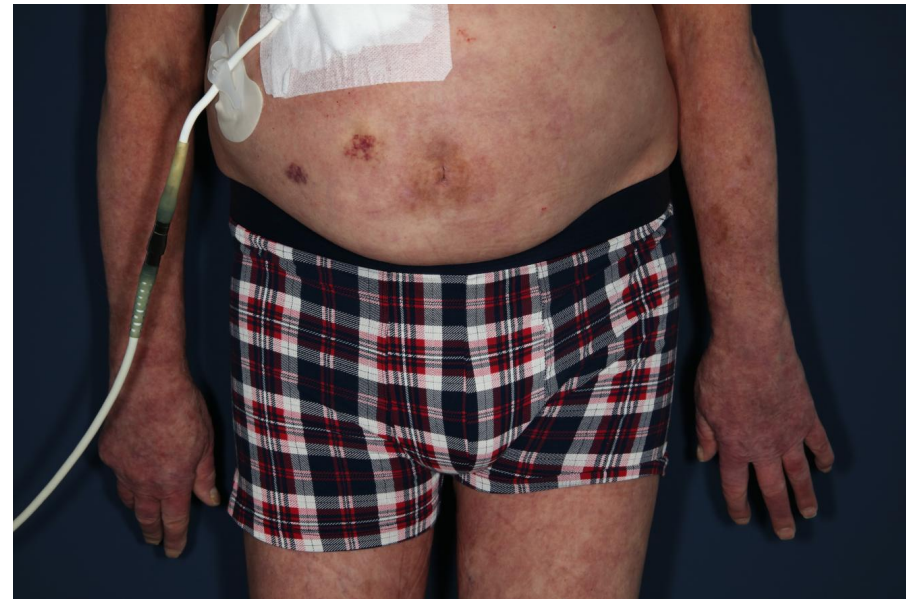
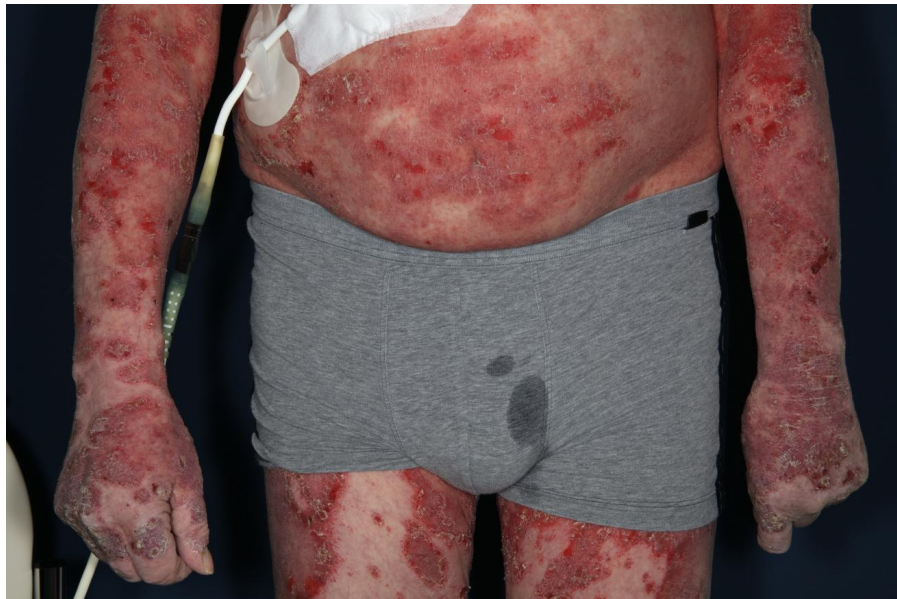

18.12.2021:

PASI 5,4

BSA 10

DLQI 3

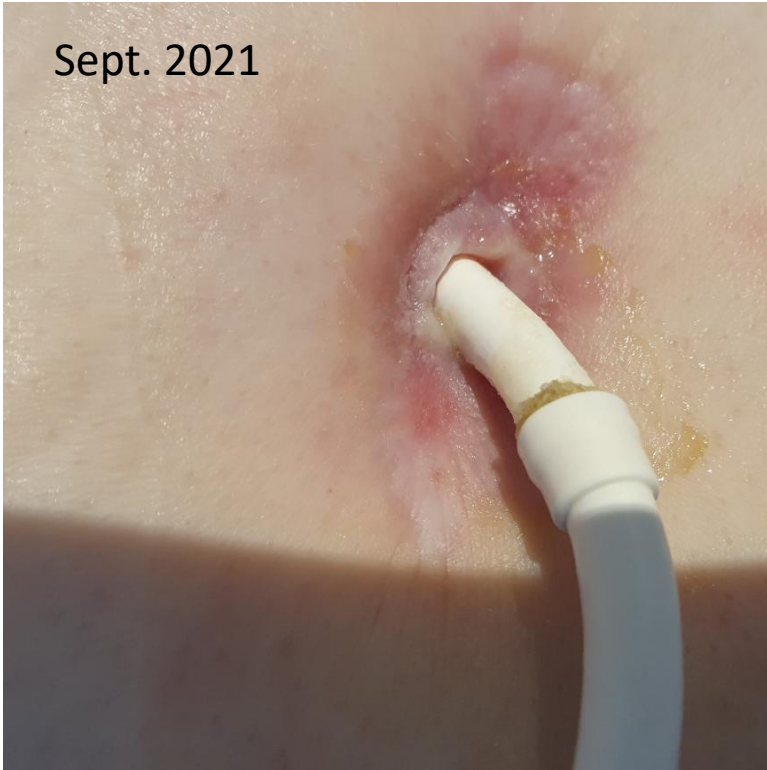

Source:
Thomas Dirschka

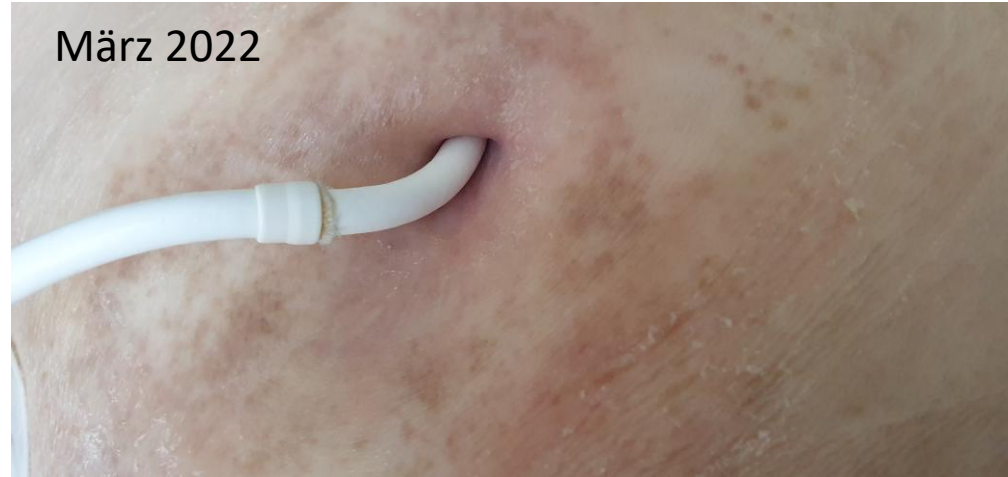Driveline: Infection resolved



Sept. 2021



März 2022



Source:
Thomas Dirschka

Conclusion



- LVADs carry the risk of sepsis due to driveline infection.
- The use of bimekizumab in a heart failure patient with an LVAD resulted in a rapid improvement in relevant severity parameters.
- The life-threatening driveline infection resolved.
- The therapy was free of adverse effects.

grateful patient



Source:
Thomas Dirschka



Case VI

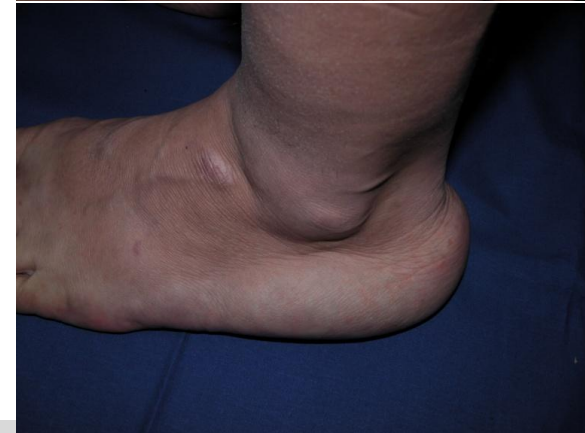
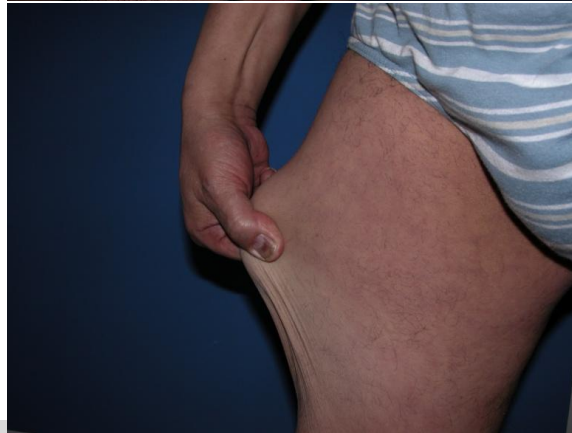
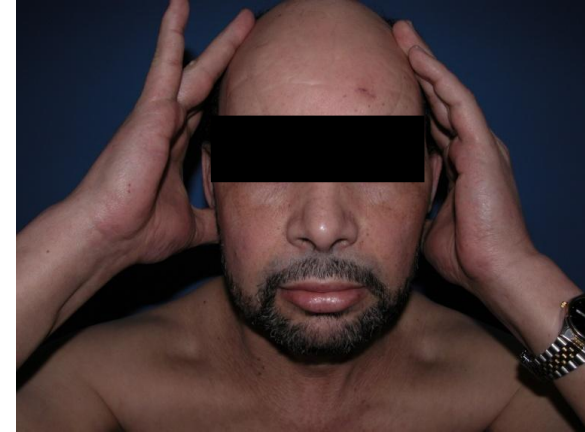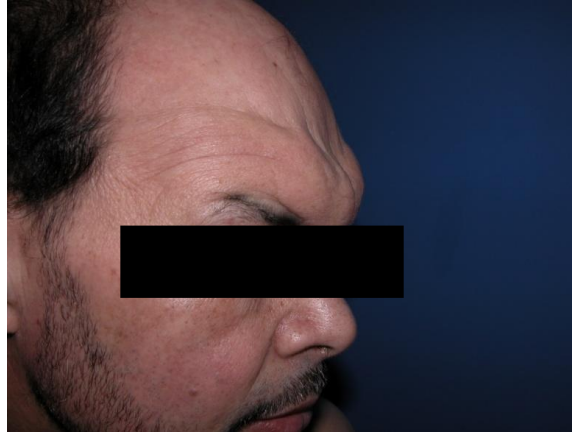Year old patient
Diffuse large B-cell lymphoma (DLBCL)
Therapy: Rituximab

Within few weeks:

Sagging of the forehead skin, rubbery consistency of the skin, swimfin-like expansion of the feet

Histology:
Loss of elastic fibres



Cutis laxa acquisita



Belongs to the "orphan diseases"

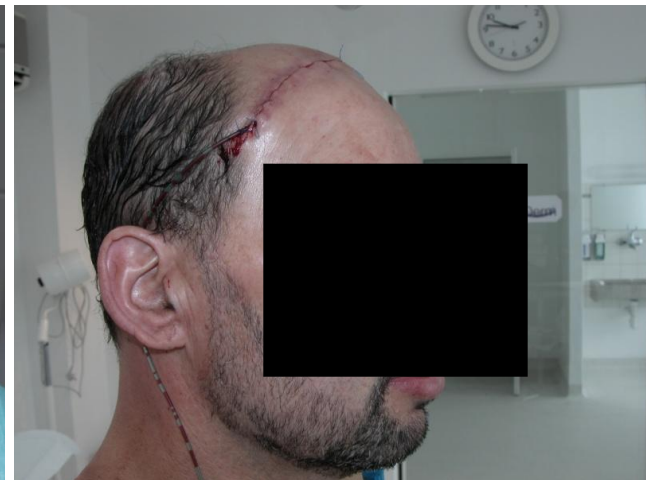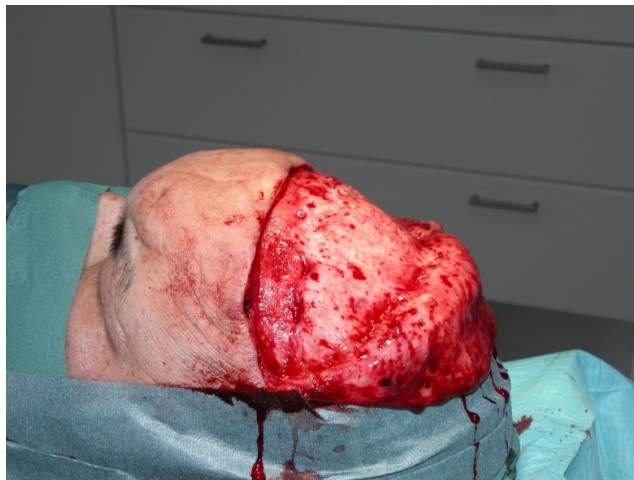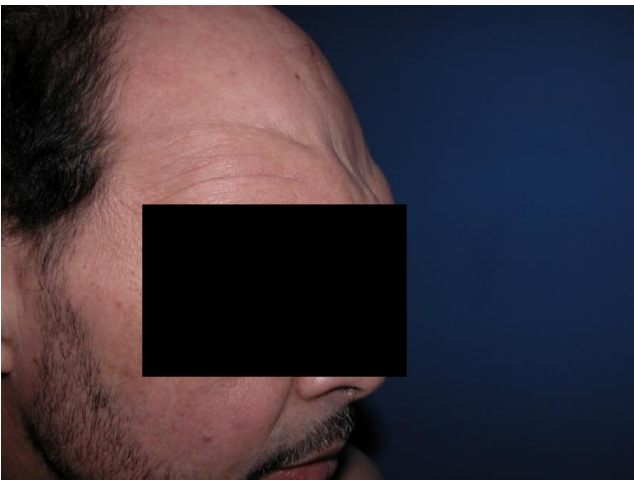Association with multiple myeloma described (few case reports)

No publication to date in the DLBCL

Therapy not described

Our therapy...

Our Therapy



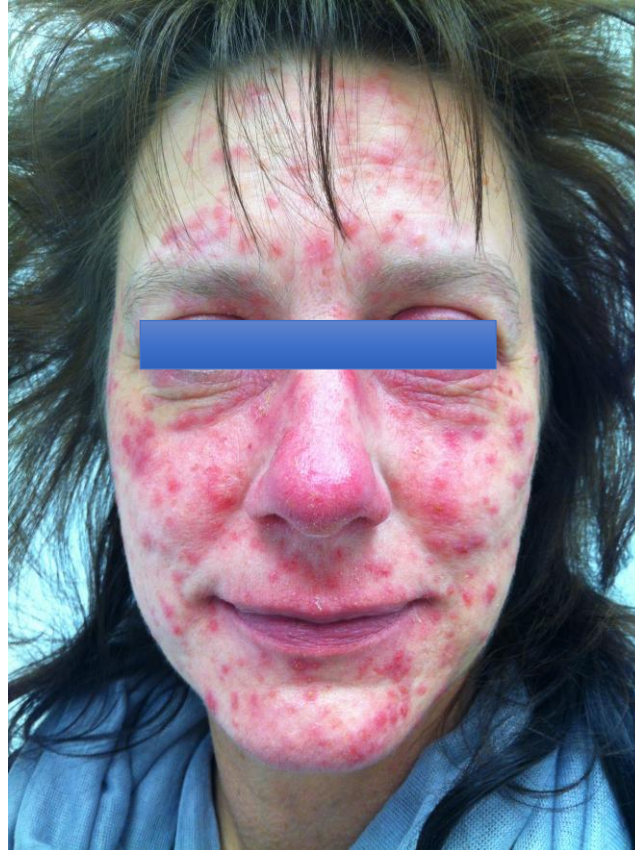

Case VII



Day 0

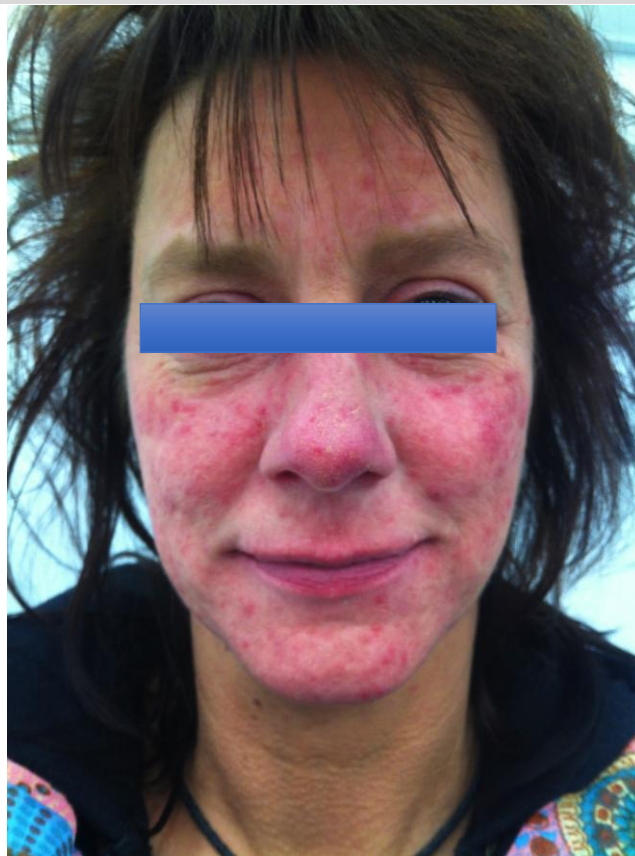42-year-old patient
Therapy: metronidazole creme
→ Not responsive





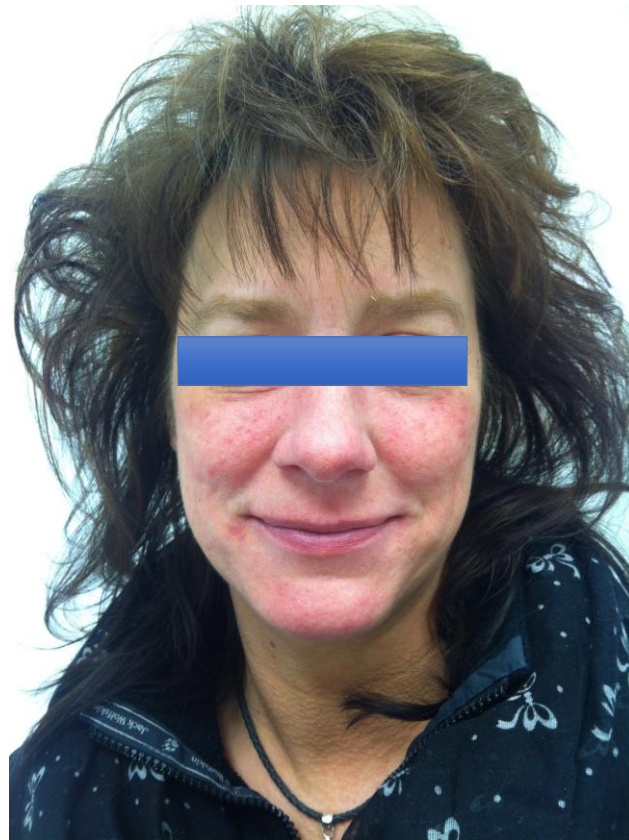Day 7

Low dose doxycycline
(modified release) 40mg/d
Topical ivermectine qid



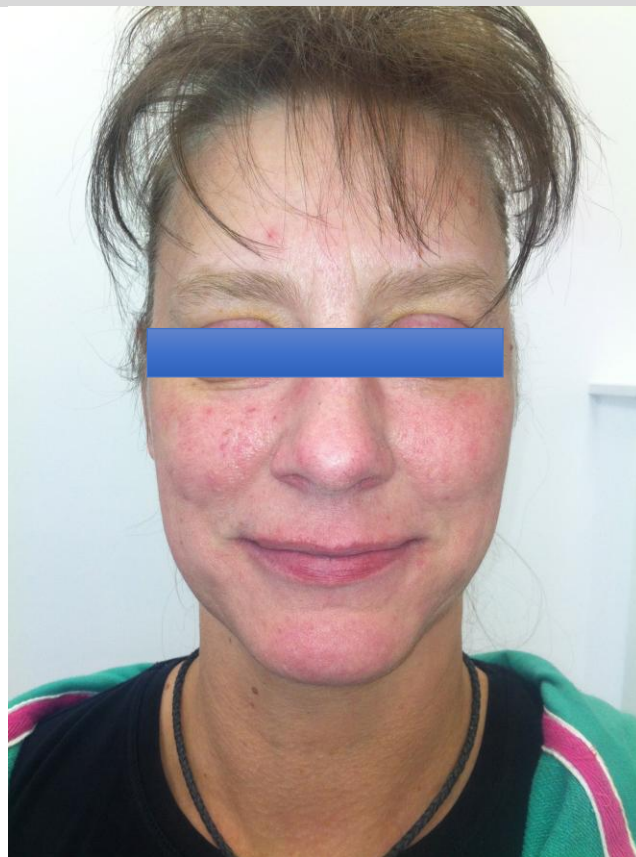

Day 21



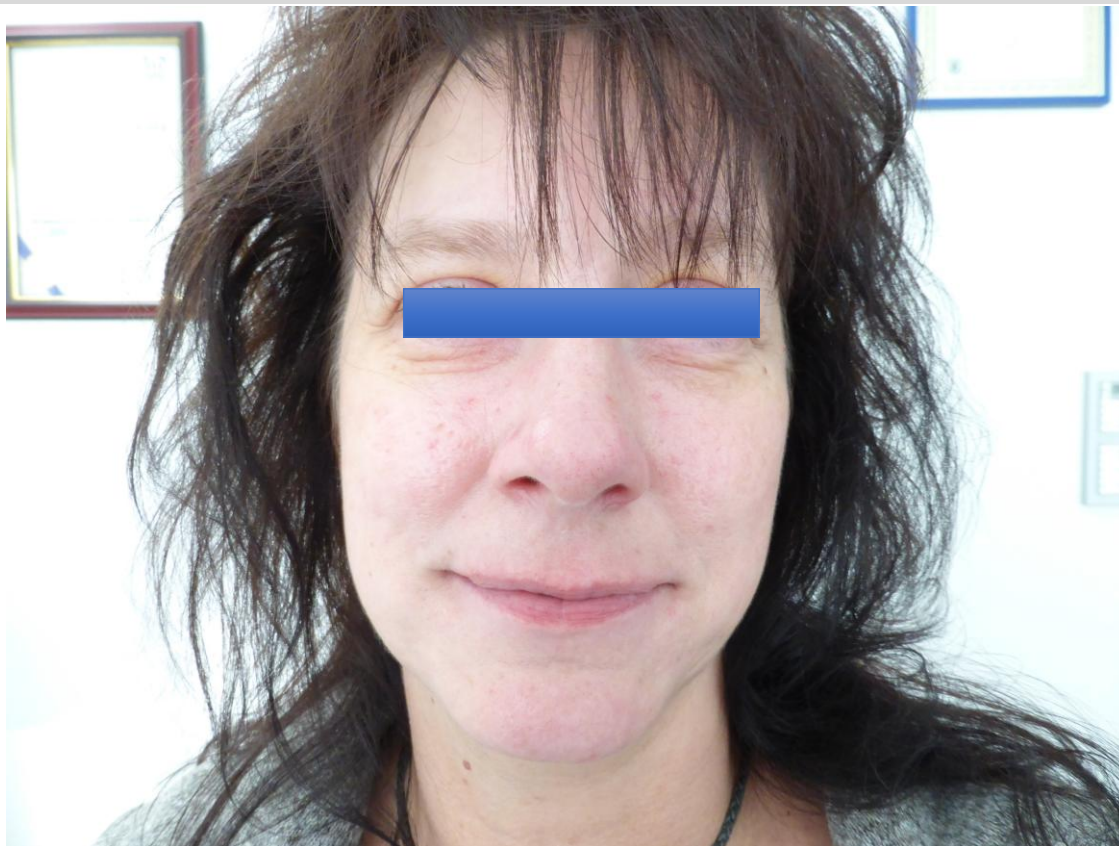

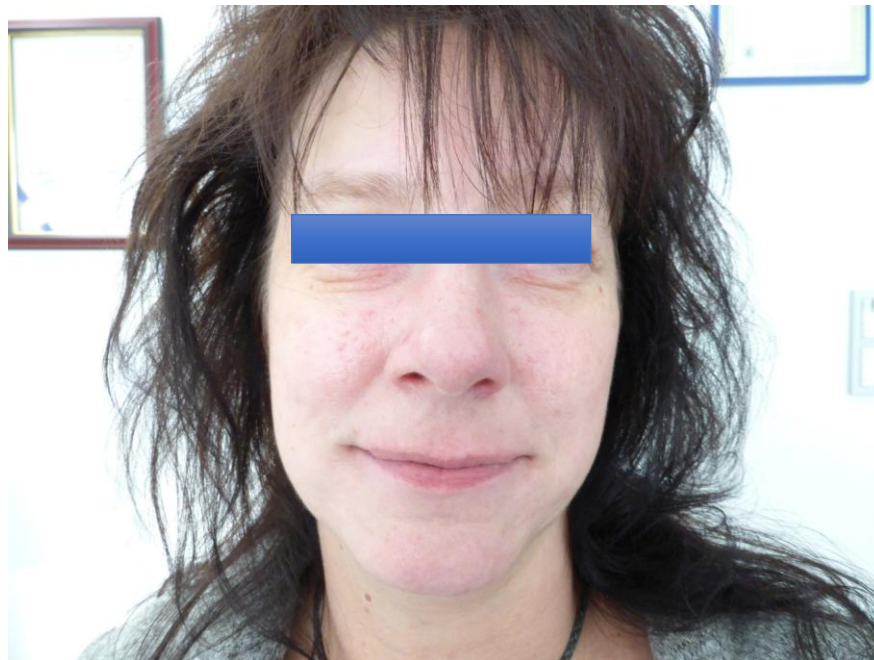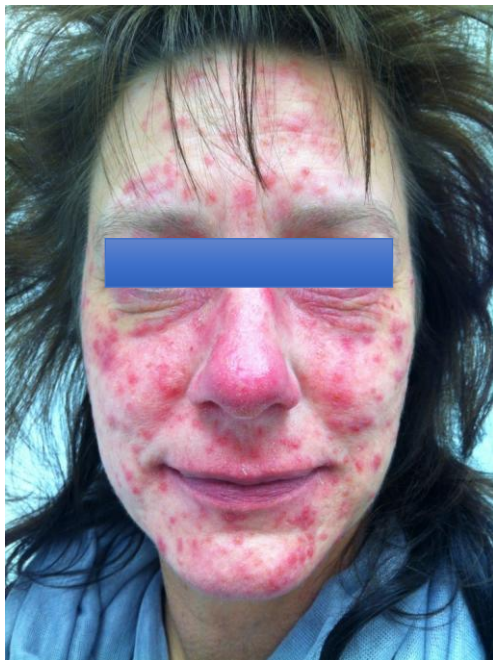Day 56





Day 112





**A Sequential Approach to the Treatment of Severe Papulopustular
Rosacea Not Responding to Traditional Treatment**

Thomas Dirschka MD,^{1,2} Lutz Schmitz MD,^{3,4} and Agota Bartha MD²
¹CentroDerm® Clinic Wuppertal, Germany

²Faculty of Health, University Witten-Herdecke, Witten, Germany

³Ruhr-University Bochum, Department of Dermatology, Bochum, Germany



Case VIII

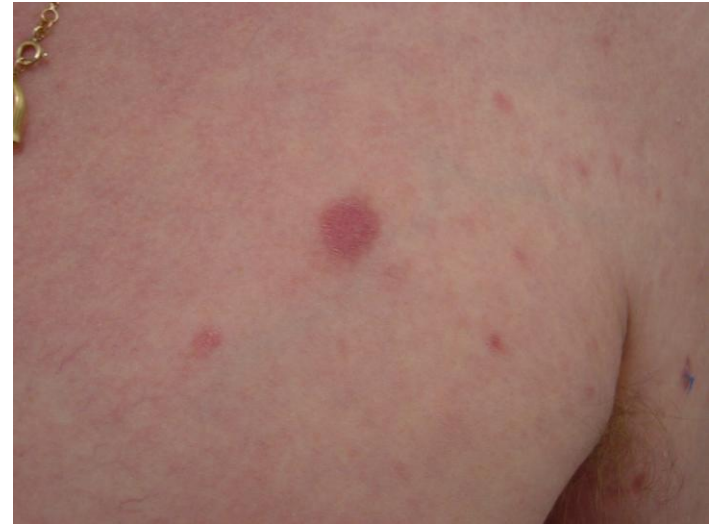
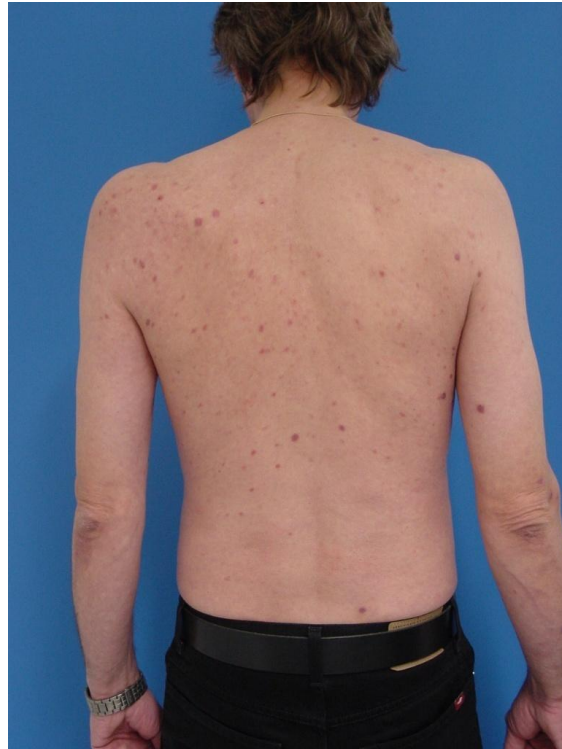
42-year-old man with a "skin rash," no itching.

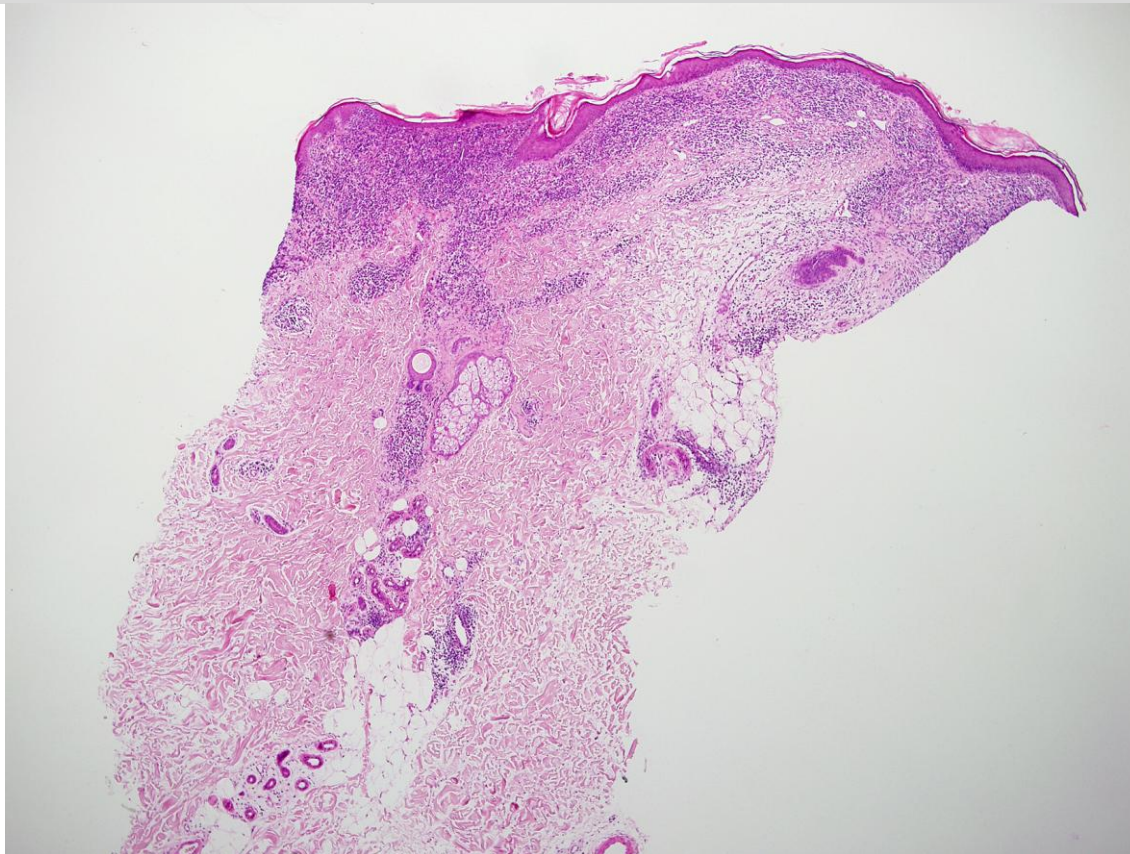
As a long-haul truck driver, he has no time to see a doctor during the pre-Christmas period.

He feels exhausted. Wounds are not healing properly, especially a lip injury. Cortisone cream has not helped.

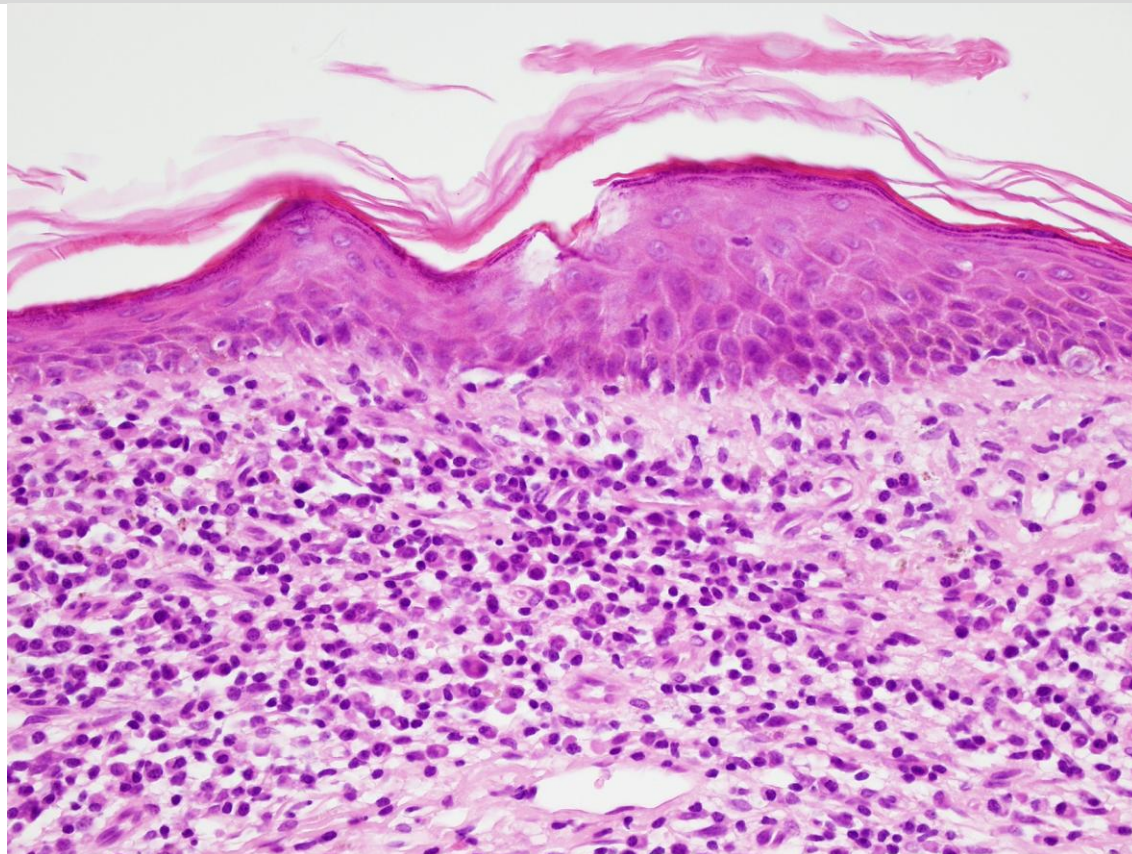
Assistant performs biopsy



What do you see?



What do you see?





Syphilis II

Several clues:

Non-itchy rash

Asymmetrical rash

Non-healing wound

Plasma cell-rich infiltrate



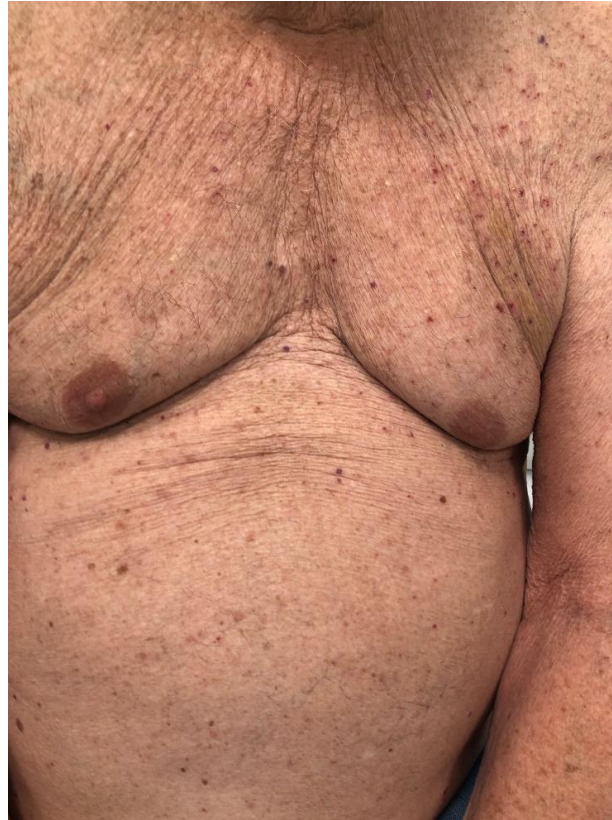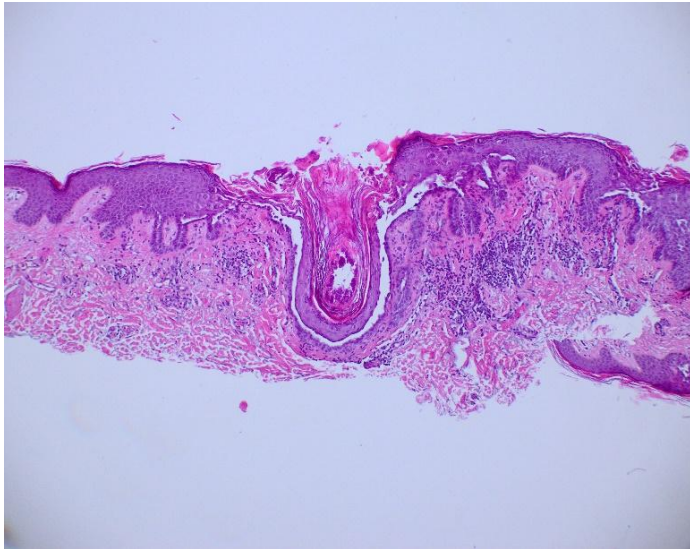
Cases IX/X

Eye diagnoses

Your diagnosis?



- Elderly men
- Trunk
- Itchy papules, excoriations



Grover's disease

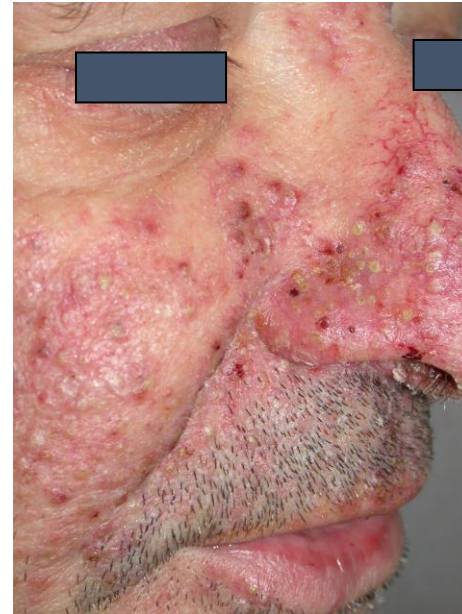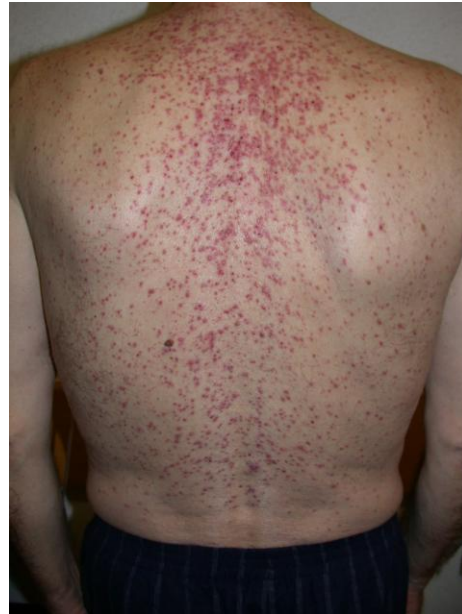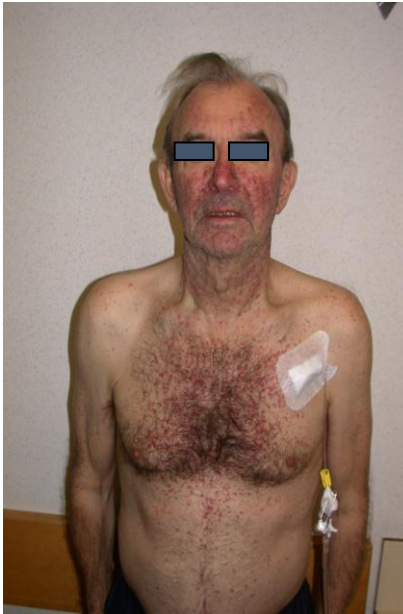Over night




What is the problem?



A patient with colorectal cancer is asked to excise a suspicious nodule on the trunk.
What other problems does this patient have?





Thanks for your kind attention!

