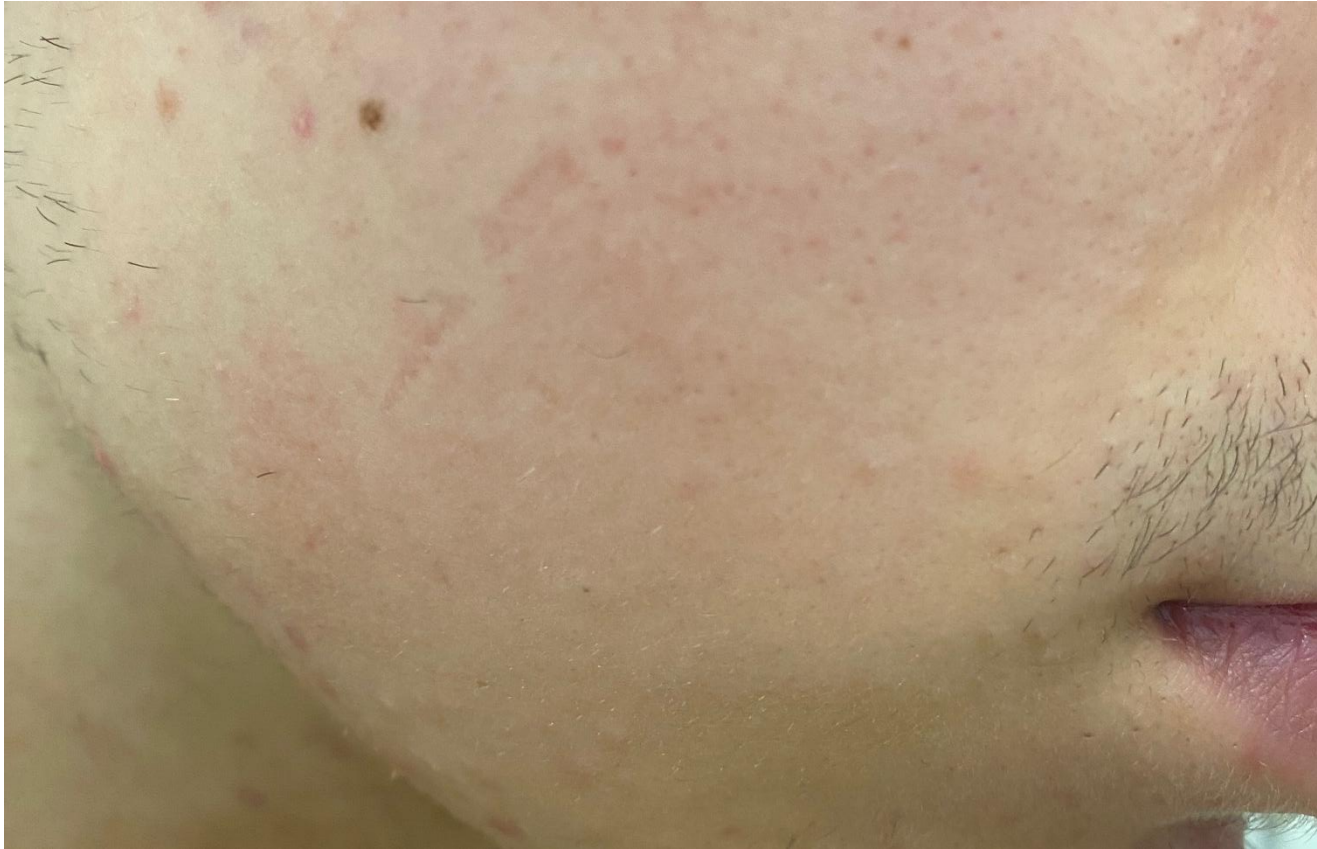
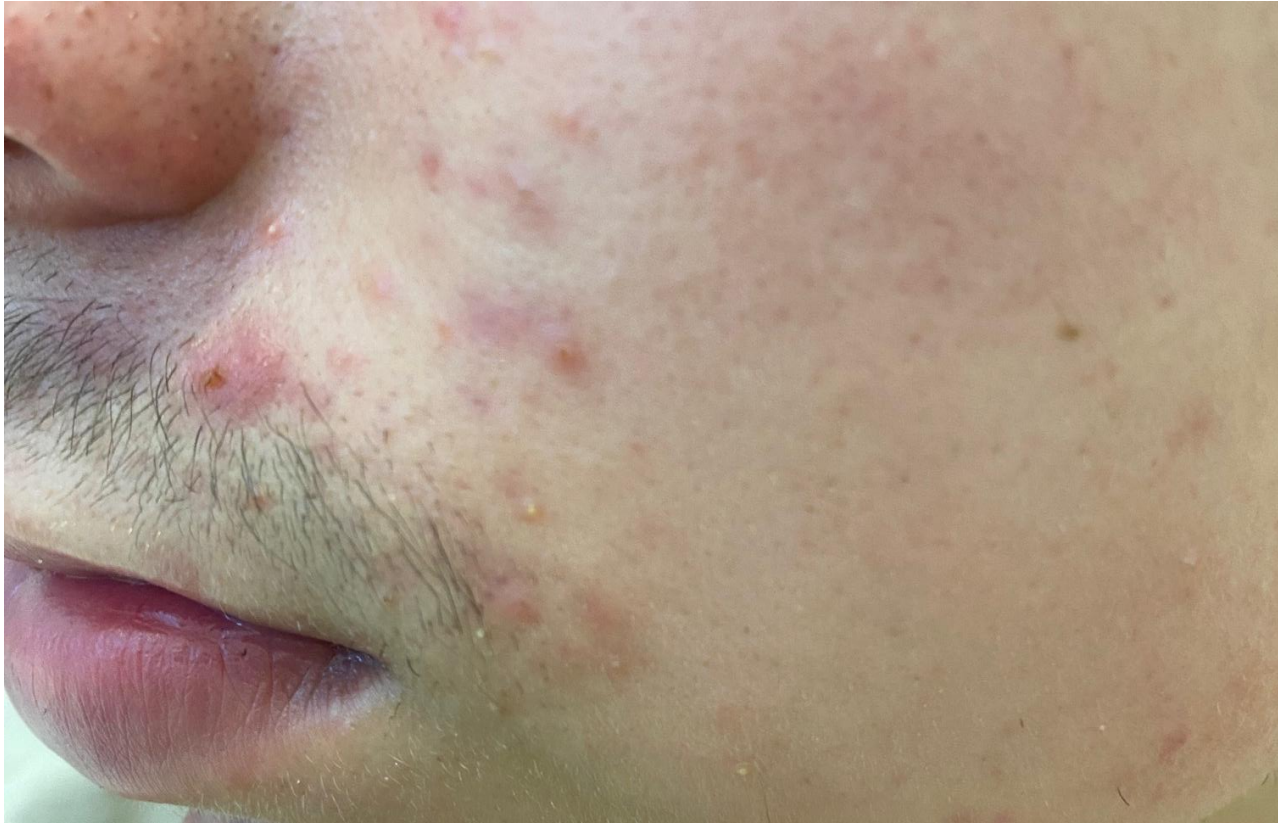
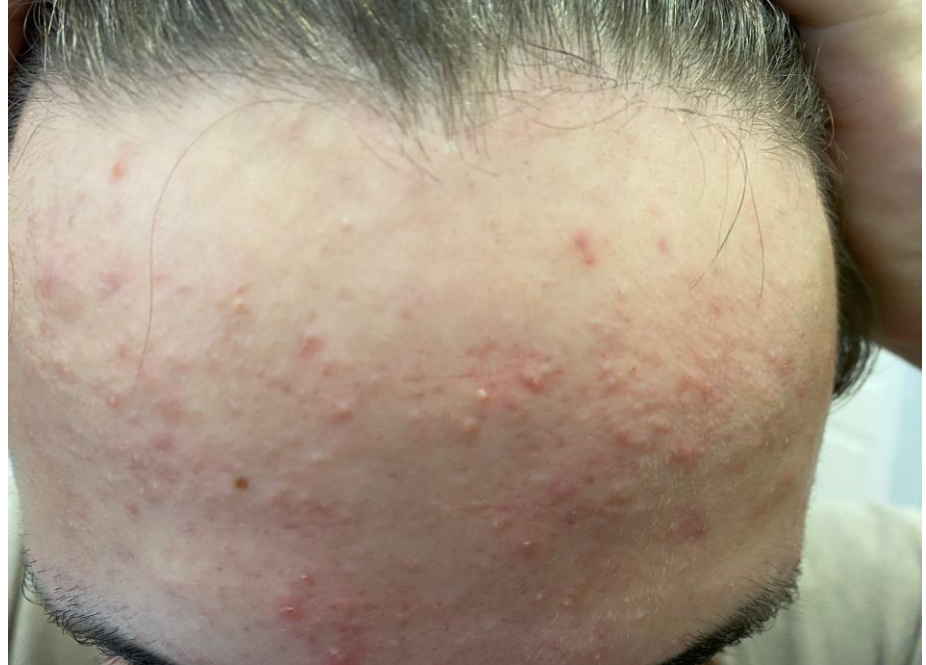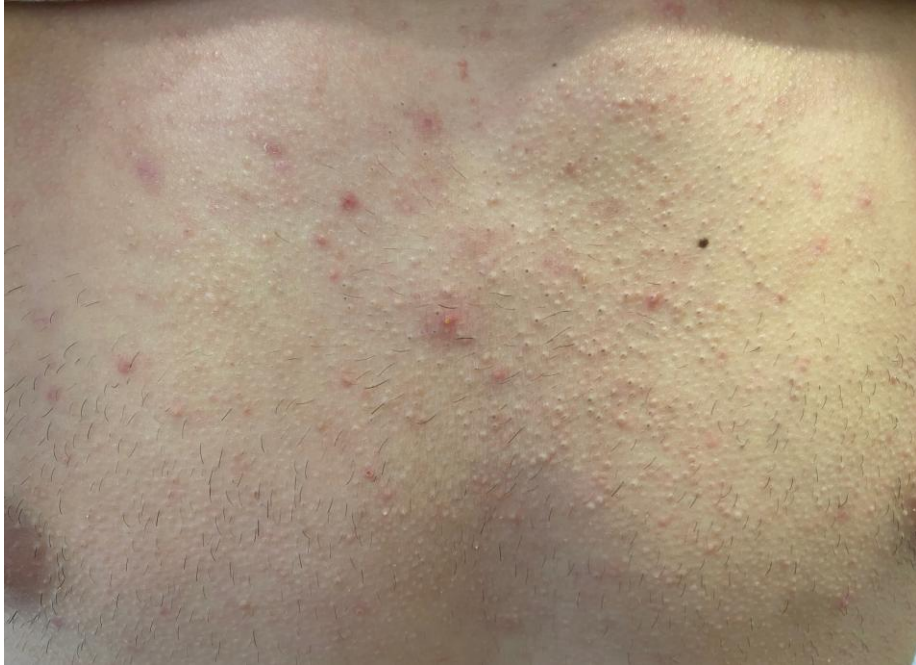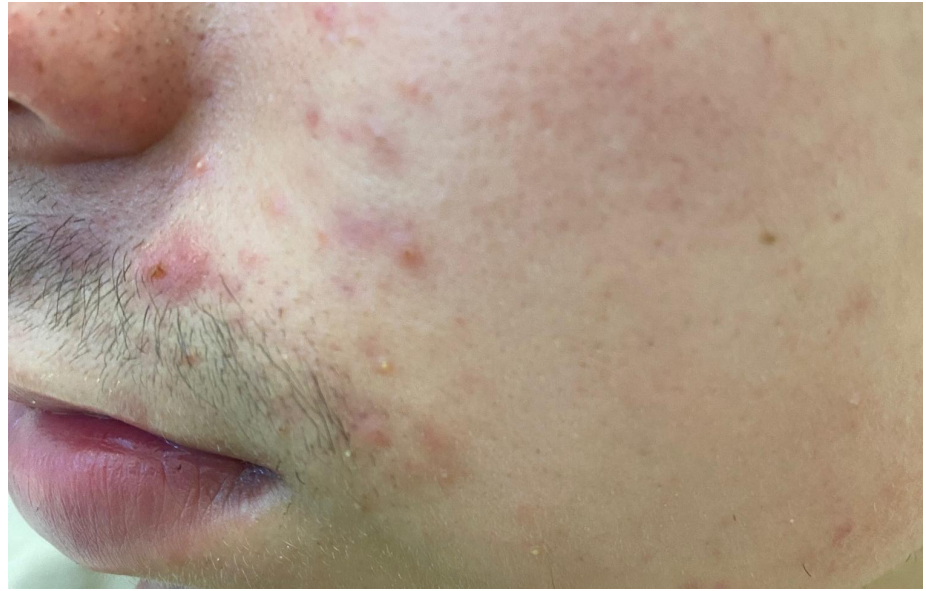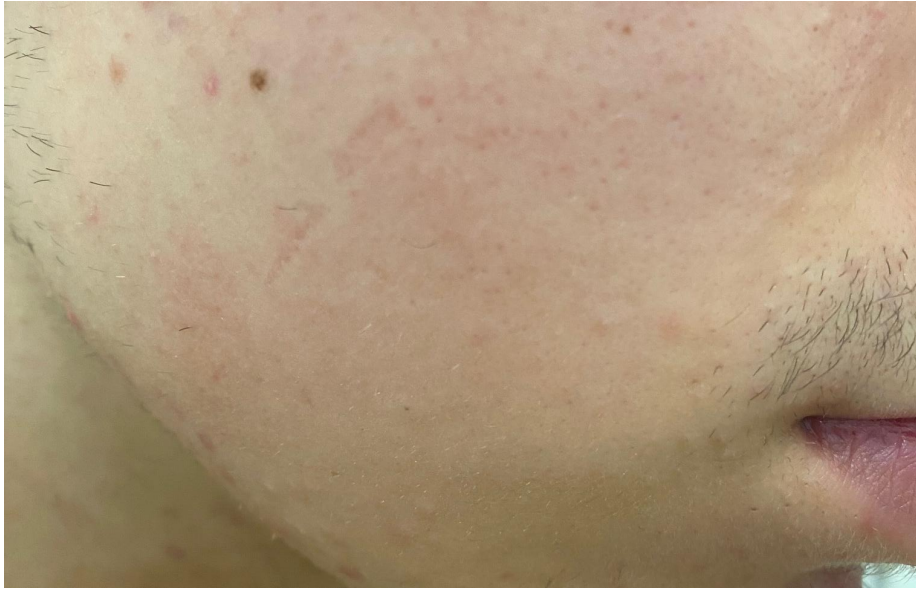Patient 1



- A. Only moisturizers
- B. Topical treatment
- C. Oral isotretinoin
- D. Send me more pictures
- E. Come to my office



- A. Only moisturizers
- B. Topical treatment
- C. Oral isotretinoin
- D. Send me more pictures
- E. Come to my office



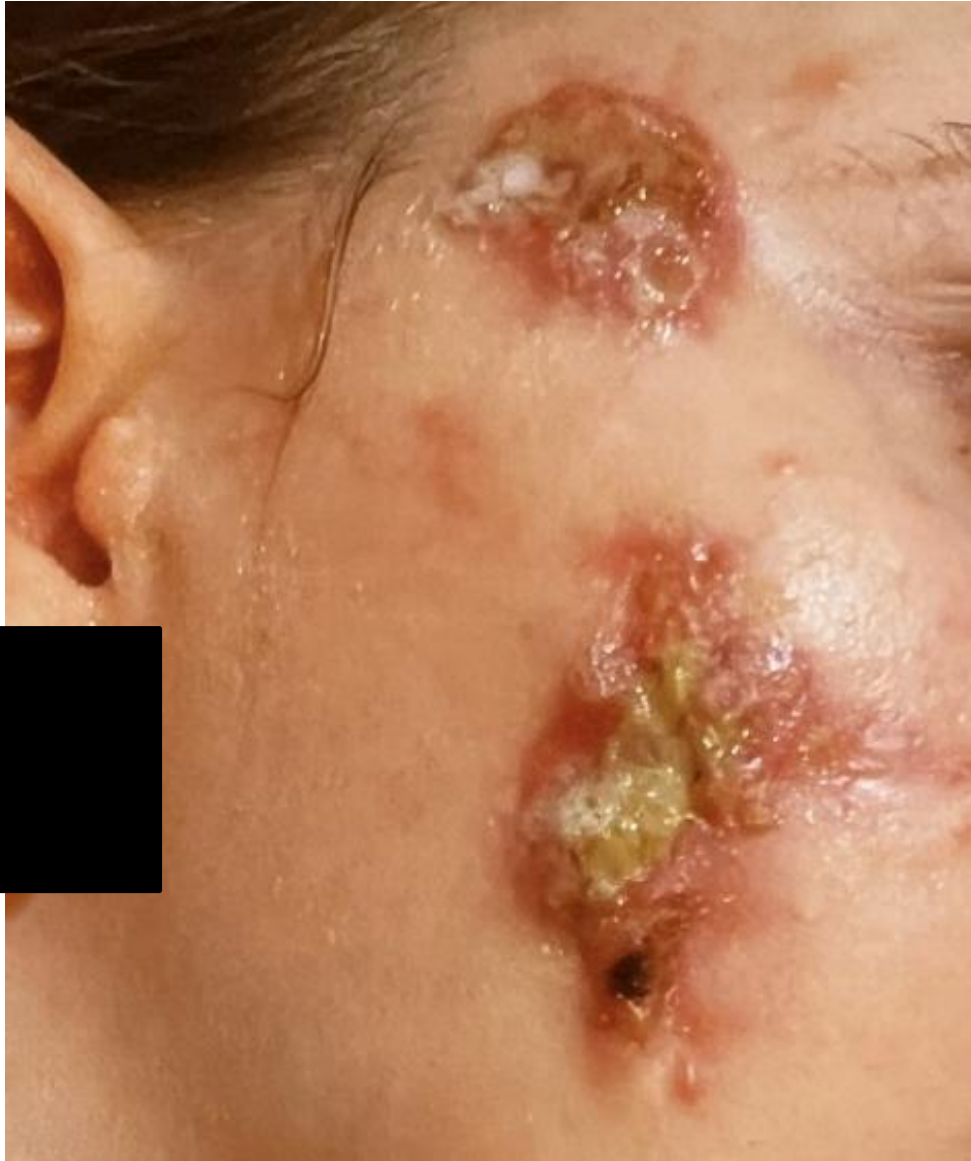(Side) effects of Isotretinoin

- Teratogenic - YES
- Dry lips and mucosa - YES
- Increases blood lipid levels - ?
- Photosensitizer - NO
- Causes depression - NO
- Dose should NOT be monitored
- Myalgia - rare
- Hyperostosis - rare

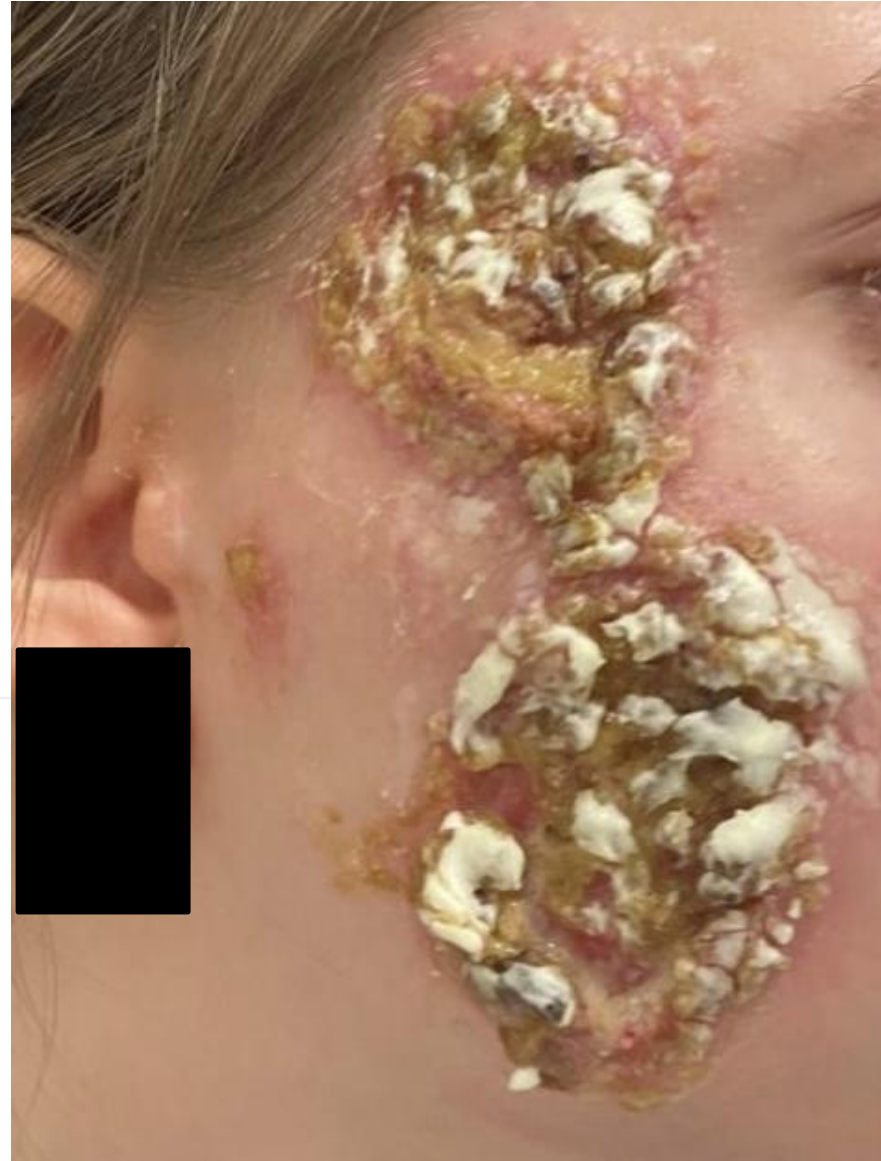

Patient 2

- 2024. july – august: isotretinoin 20mg
- 2024. december: isotretinoin again 20mg with per os steroid 16mg/day

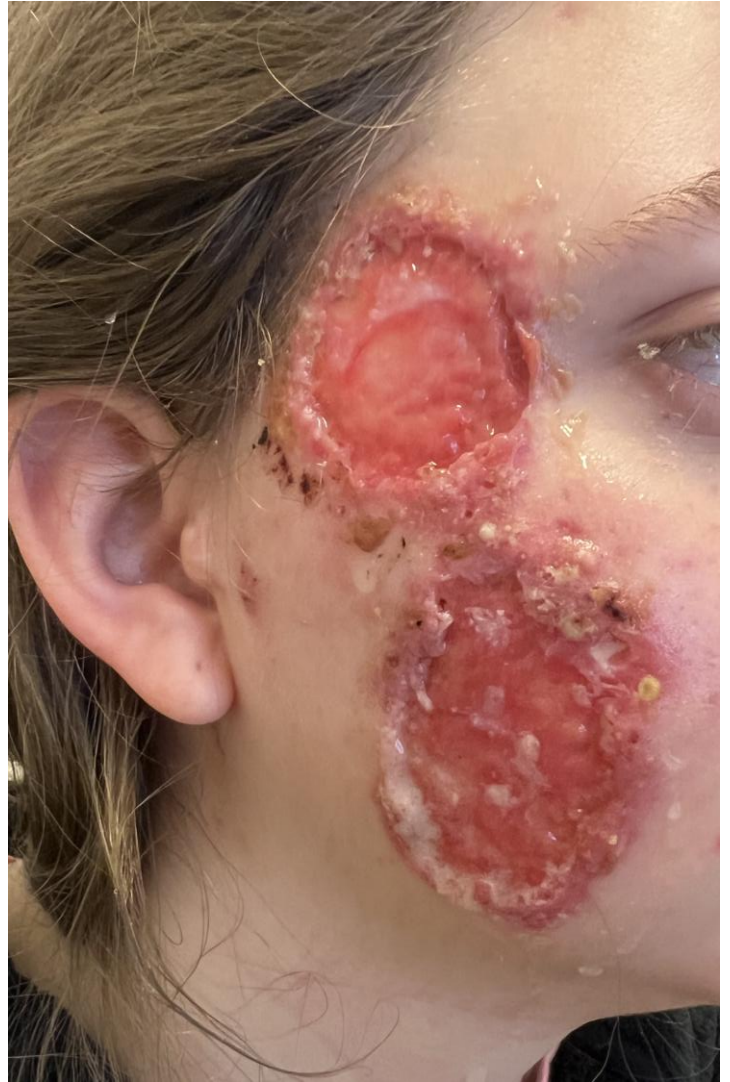
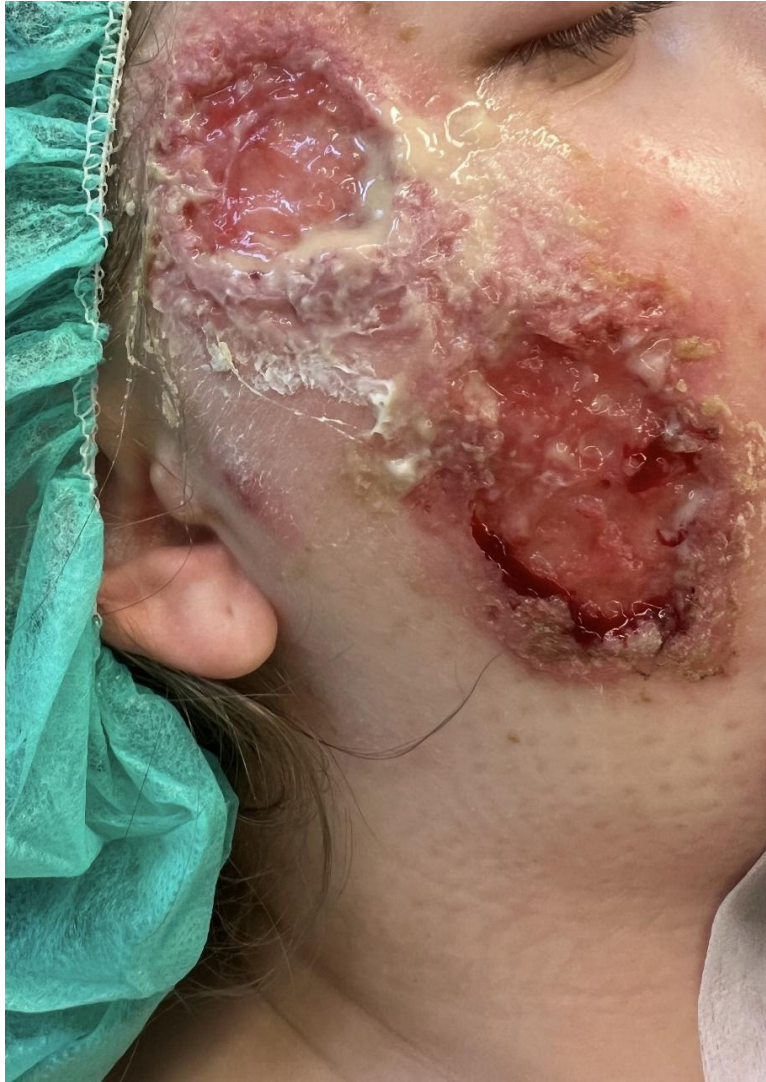
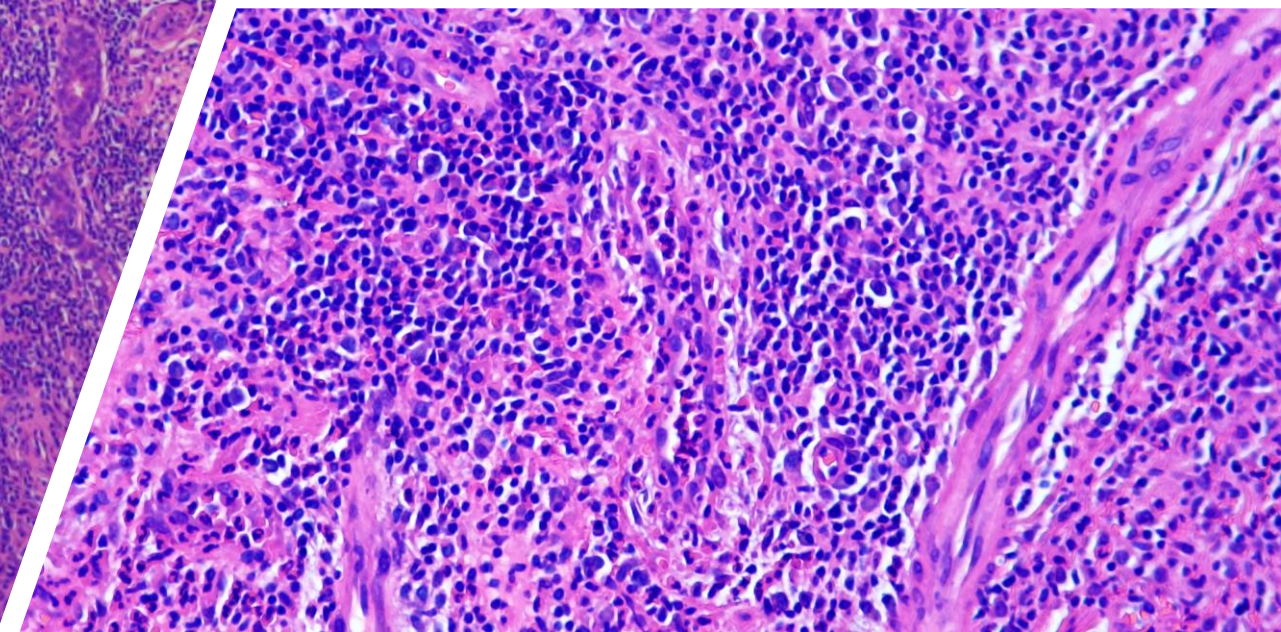
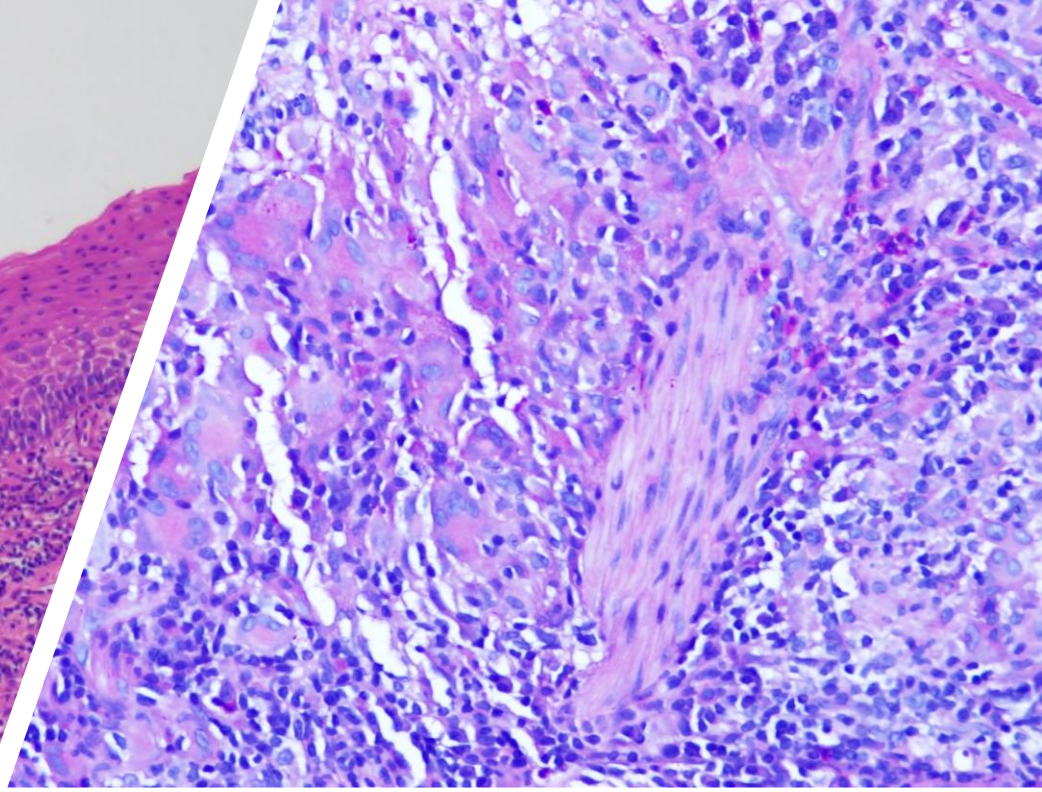
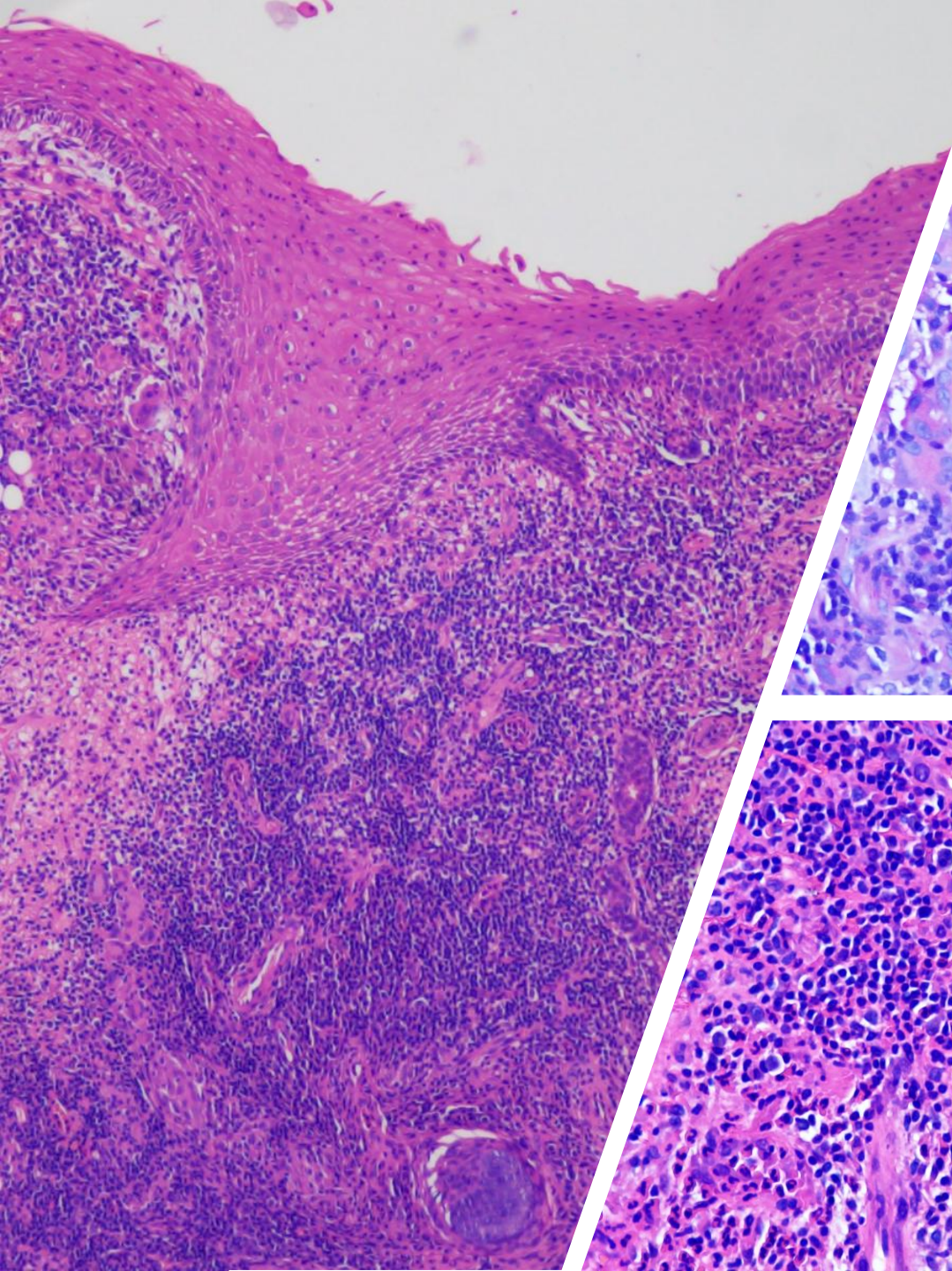
2024. december



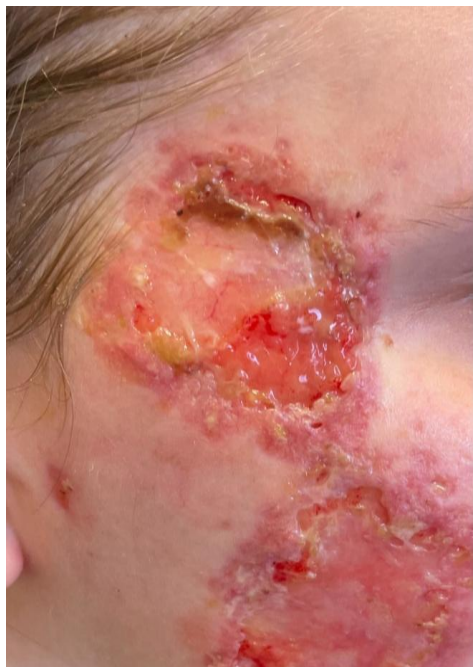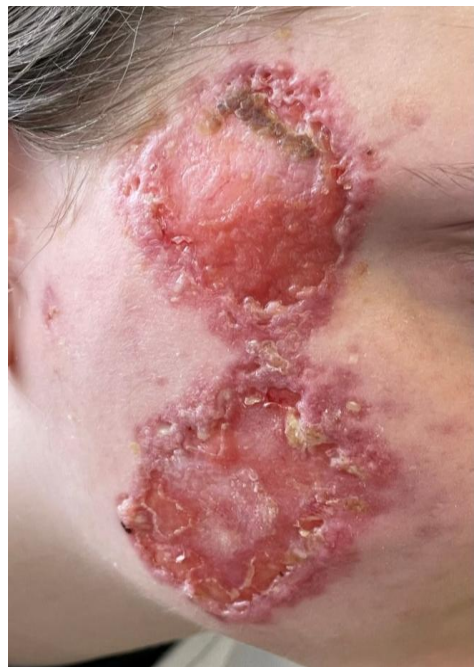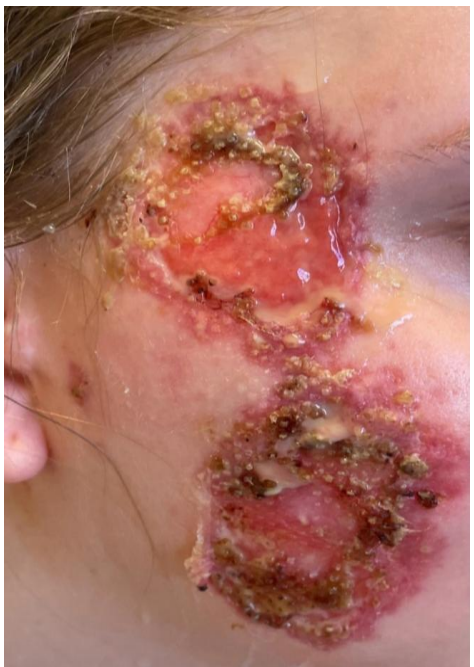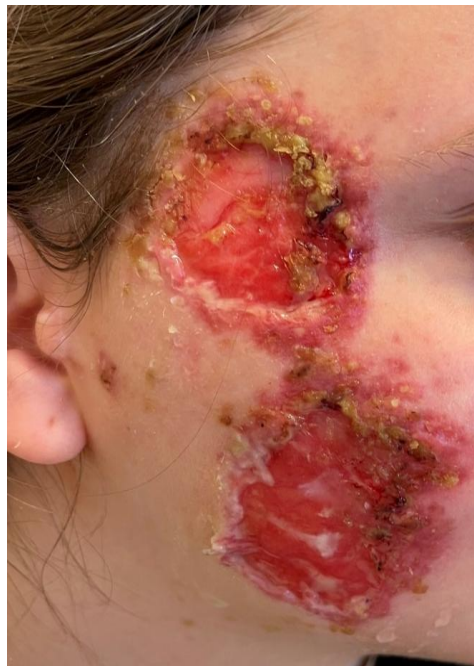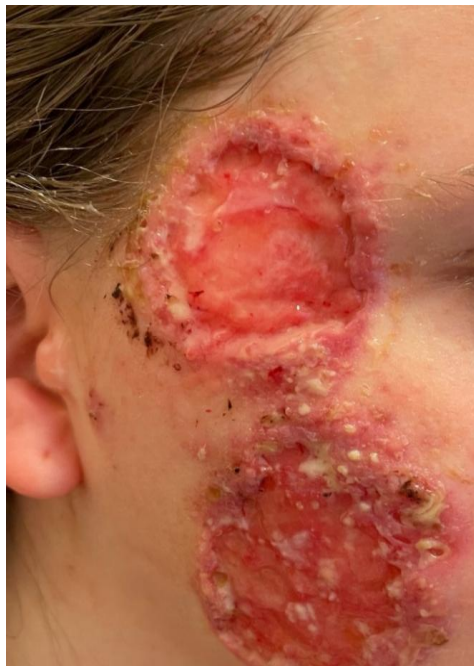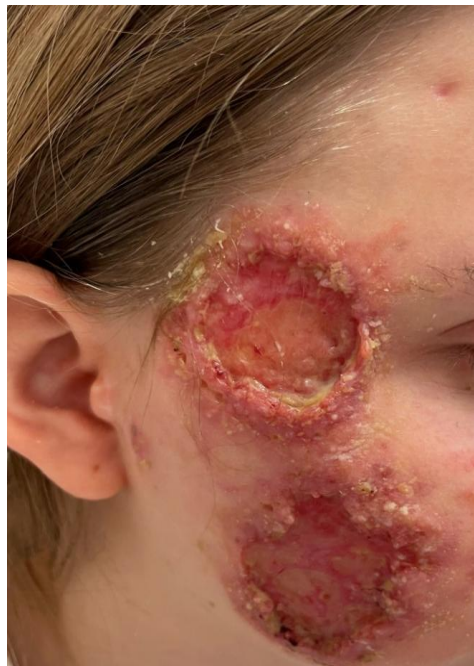2025. february

- Terbinafine 250mg
- Cefuroxime 2 X 500mg

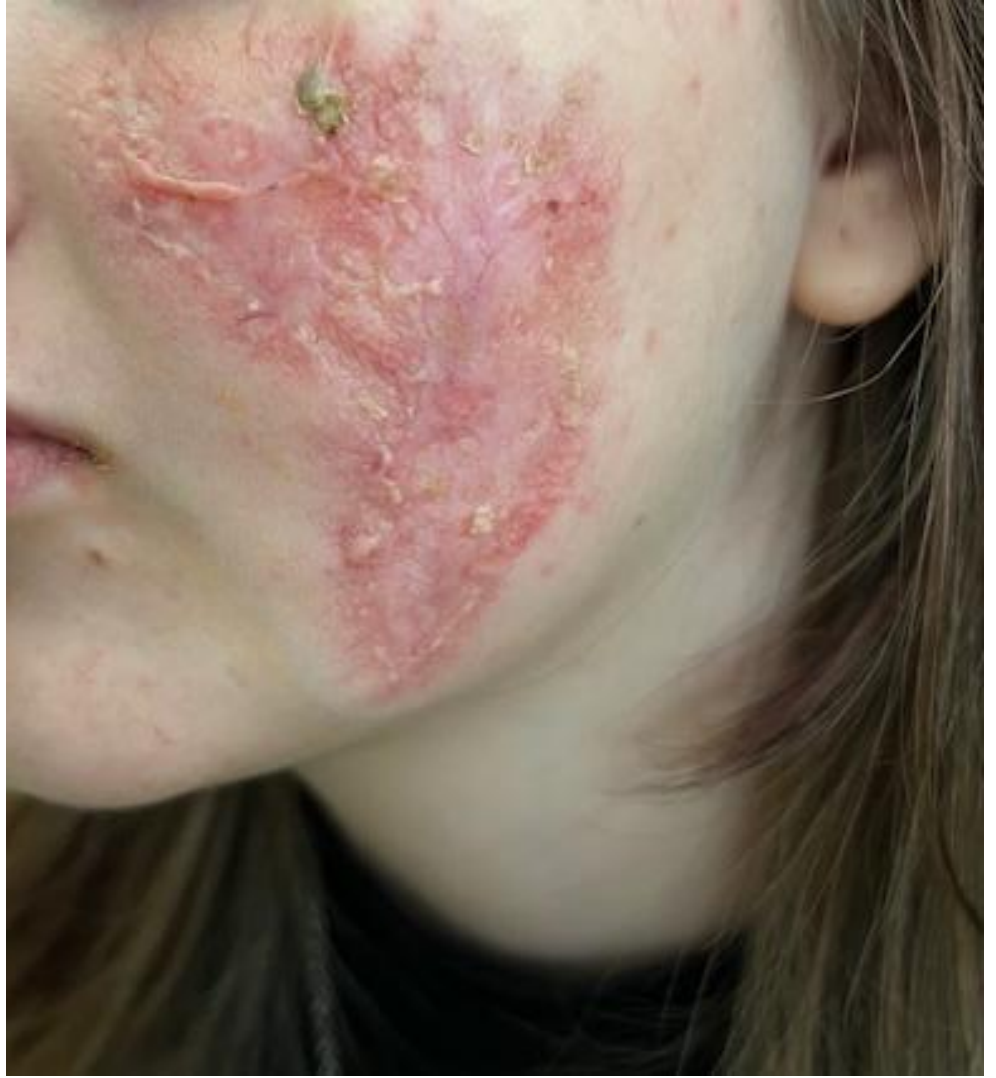
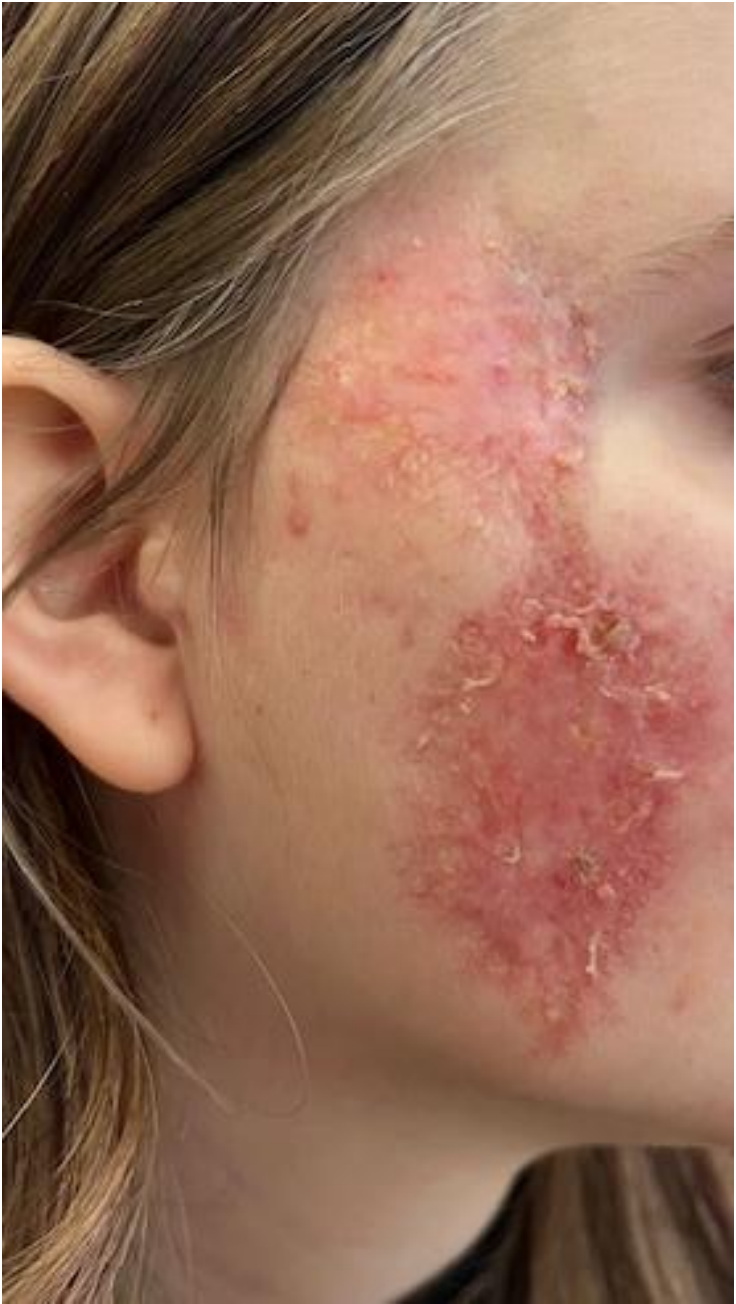


- Steroid per os: 2025.02.10 –
- + Methotrexate: 2025. 04. 01 – 2025. 07. 09.
- + Cyclosporine: 2025.07.09 - 2025. 10.01.
- + Dapsone: 2025.10.01 - 2025.10.08.



- Steroid per os: 2025.02.10 –
- + Methotrexate: 2025. 04. 01 – 2025. 07. 09.
- + Cyclosporine: 2025.07.09 - 2025. 10.01.
- + Dapsone: 2025.10.01 - 2025.10.08.
- + Adalimumab: 2025.10.08 -

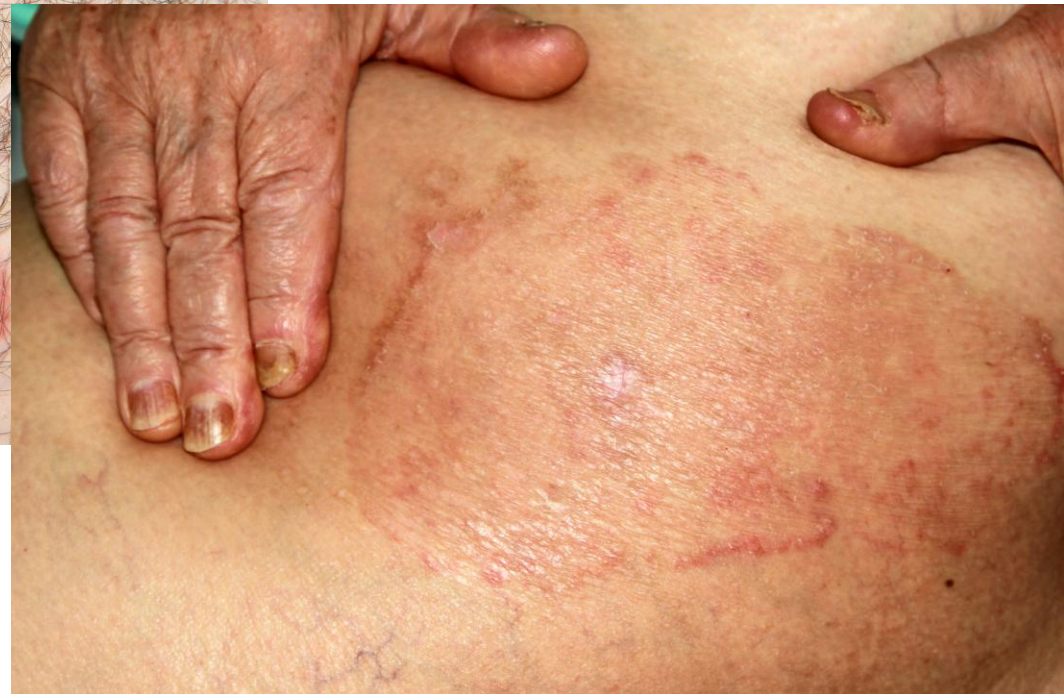
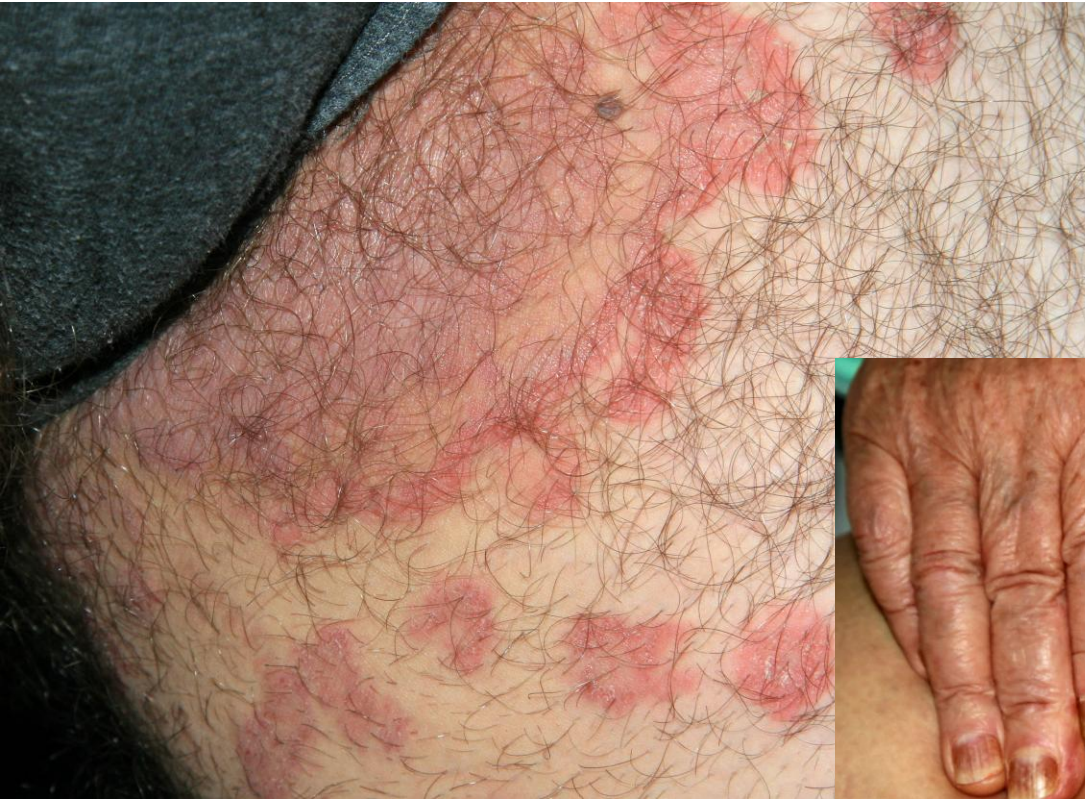
PAPA	PAPASH	PASH	PAC	SAPHO
<u>Pyogenic Arthritis</u>	<u>Pyogenic Arthritis</u>	<u>Pyogenic Arthritis</u>	<u>Pyoderma Gangrenosum</u>	<u>Synovitis</u>
<u>Pyoderma Gangrenosum</u>	<u>Pyoderma Gangrenosum</u>	<u>Suppurative Hidradenitis</u>	<u>Acne</u>	<u>Acne</u>
<u>Acne</u>	<u>Acne</u>		<u>Ulcerative Colitis</u>	<u>Pustulosis palmoplantaris</u>
	<u>Suppurative Hidradenitis</u>			<u>Hyperostosis</u>
				<u>Osteitis</u>

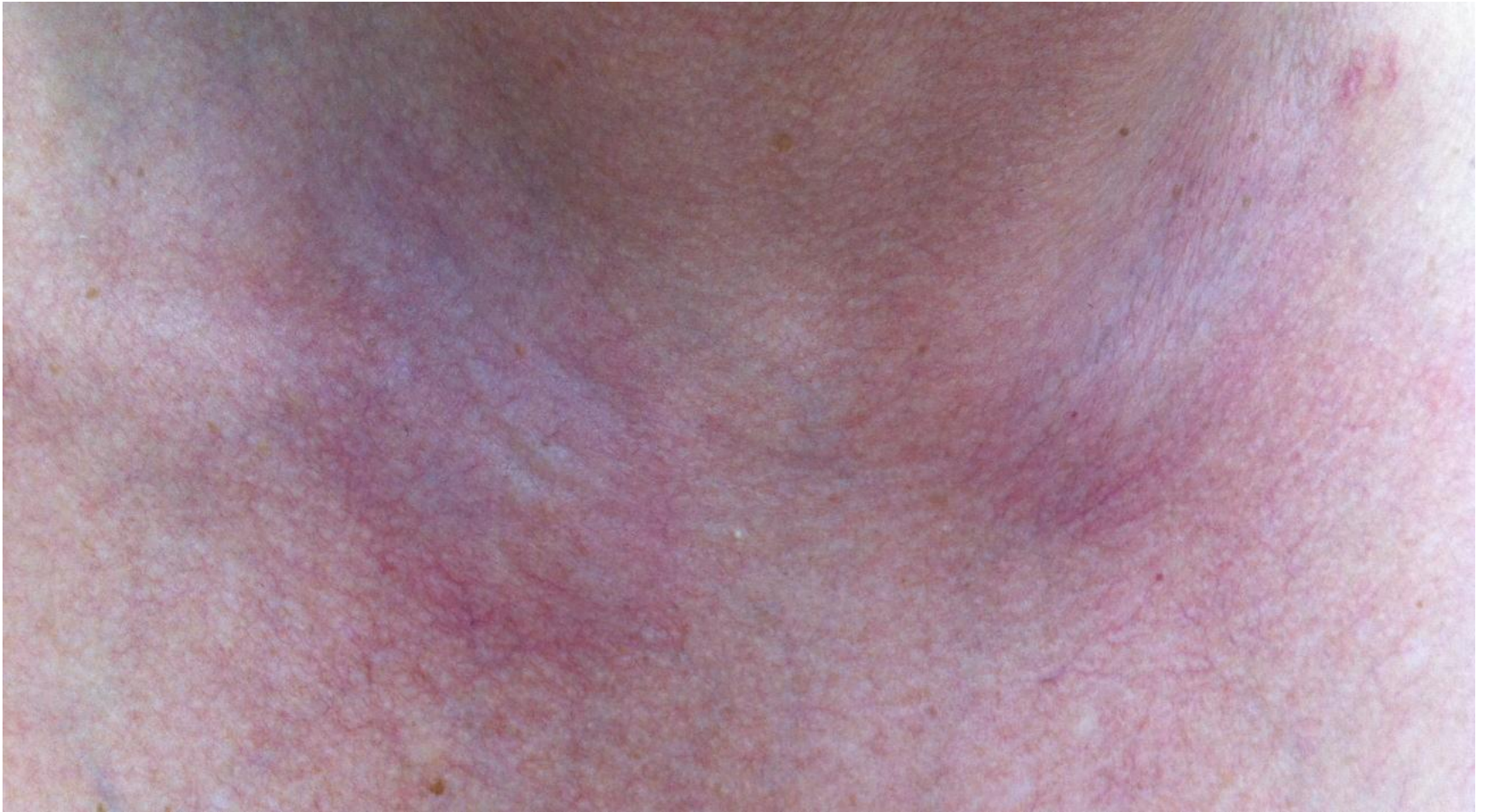Adapted from: Gerd Plewig. AAD 2017, U069: PAPA, PASH, and PAPASH Syndromes

Patient(s) 3

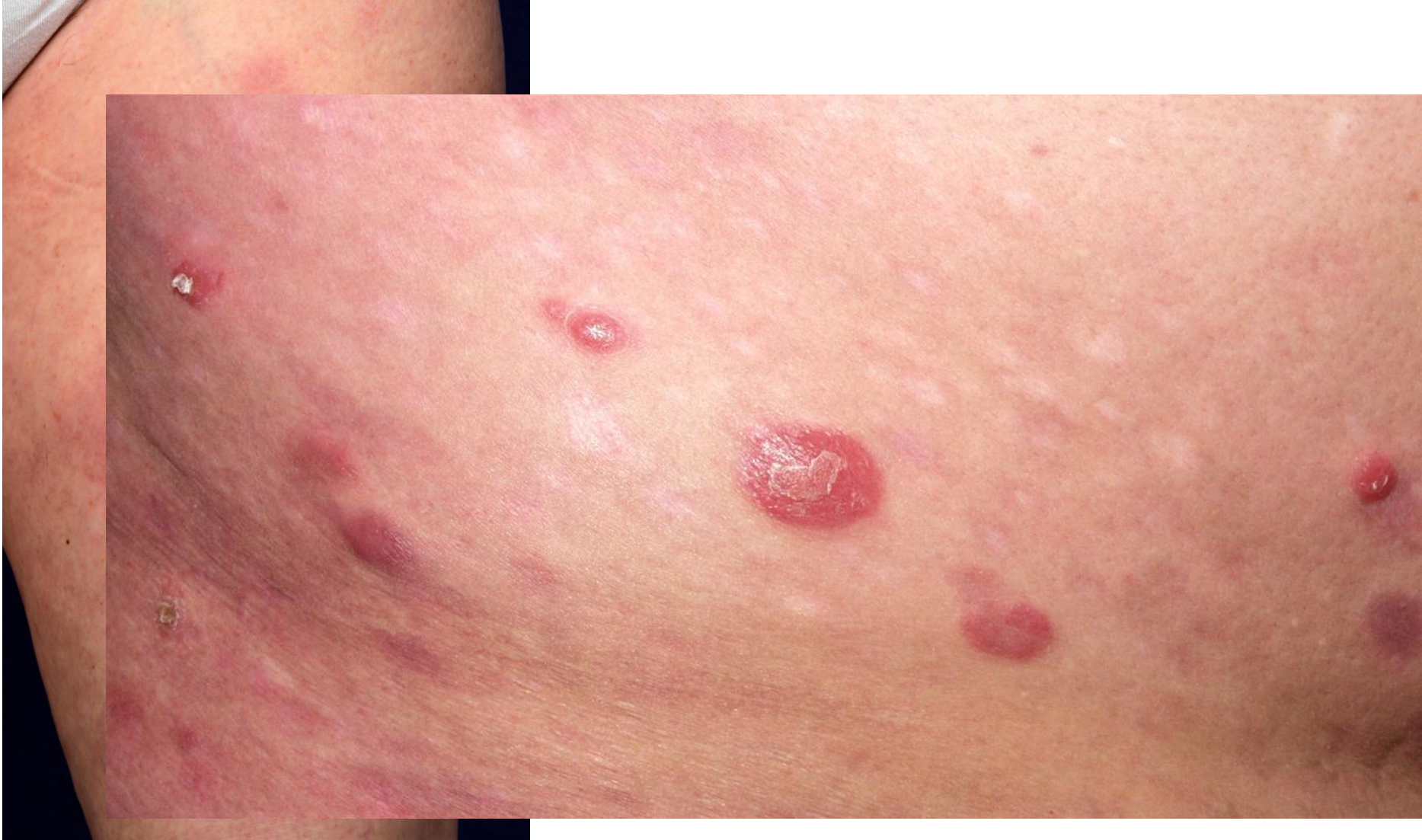Tinea corporis



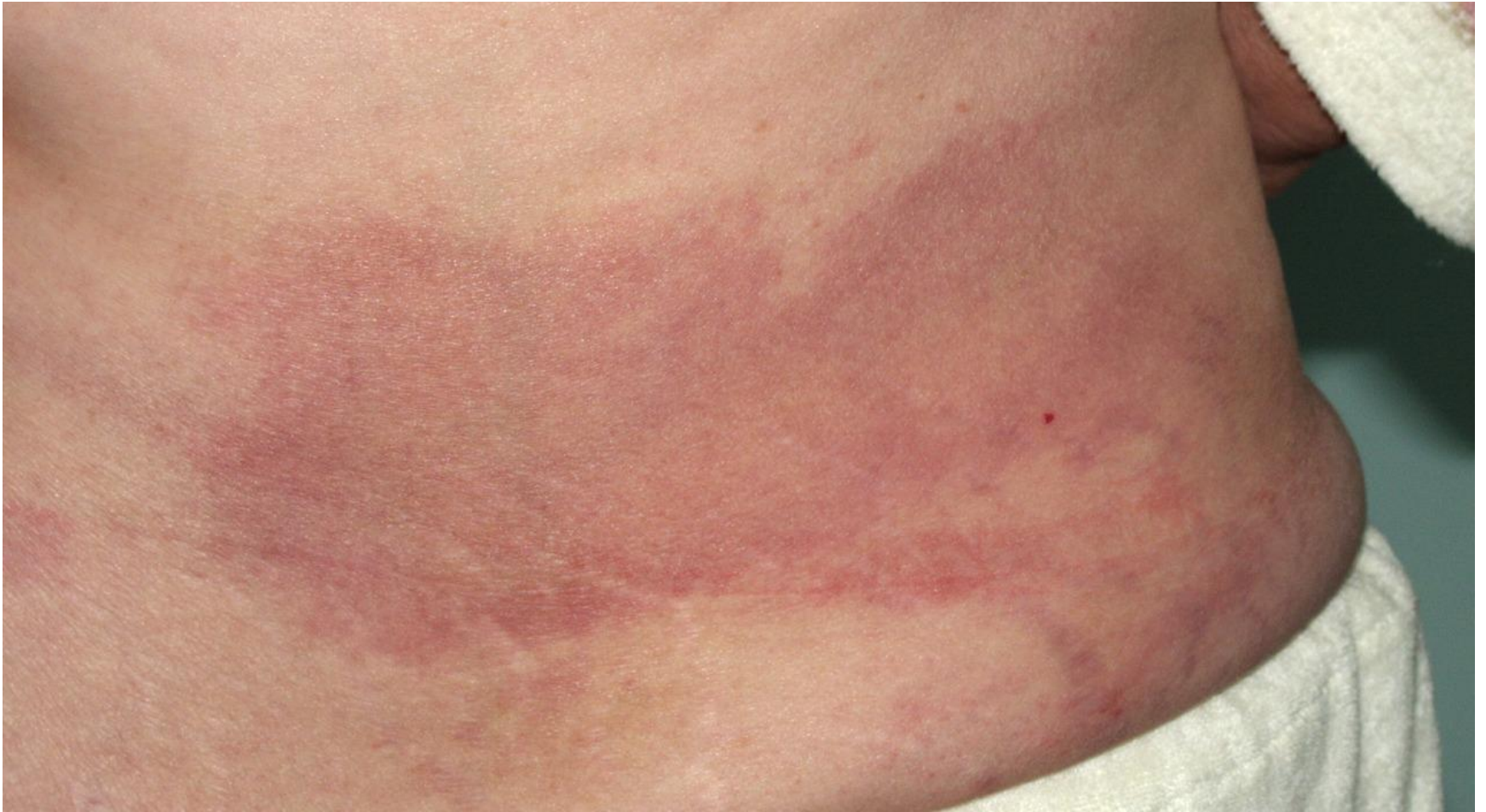Morphea



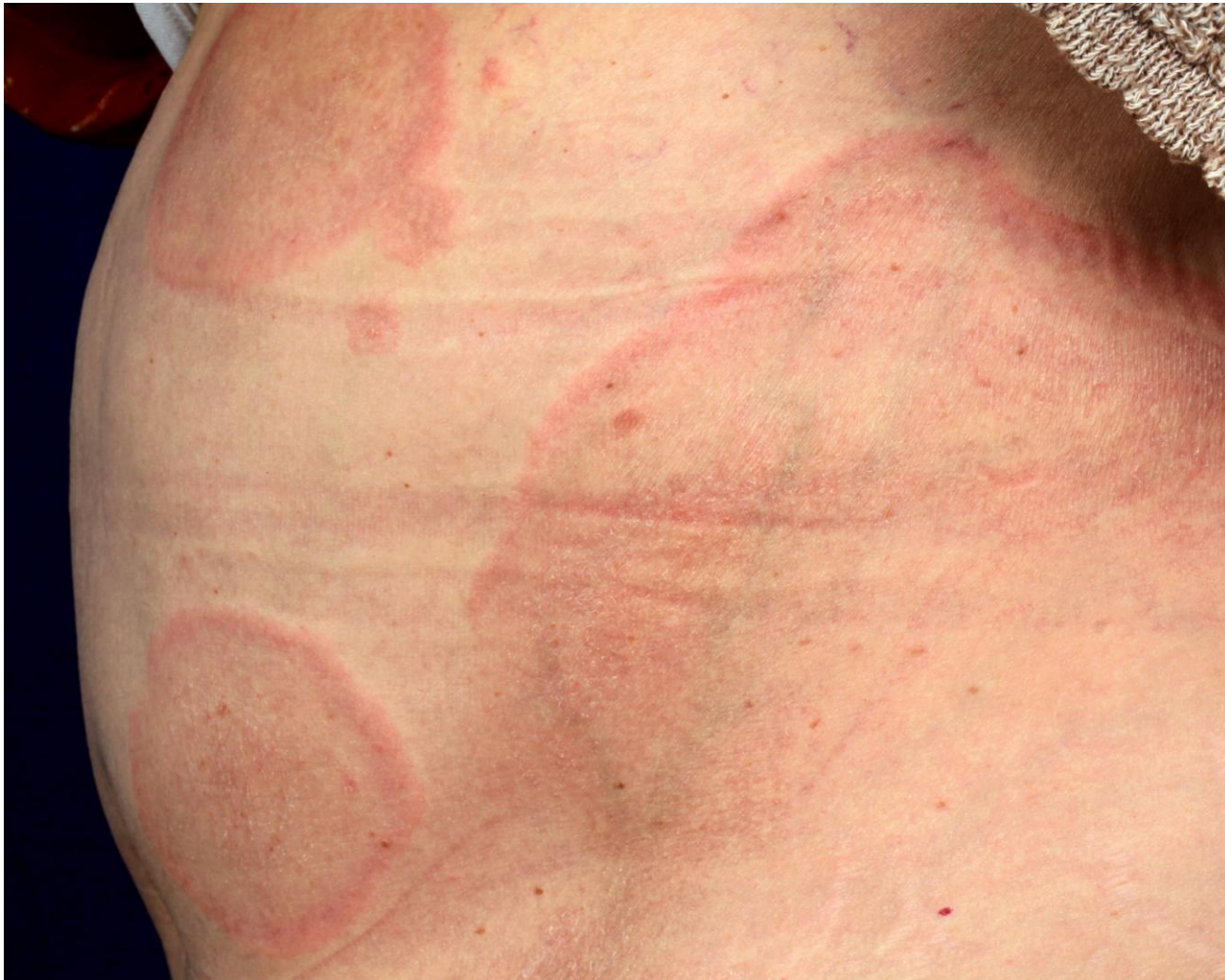Mycosis fungoides



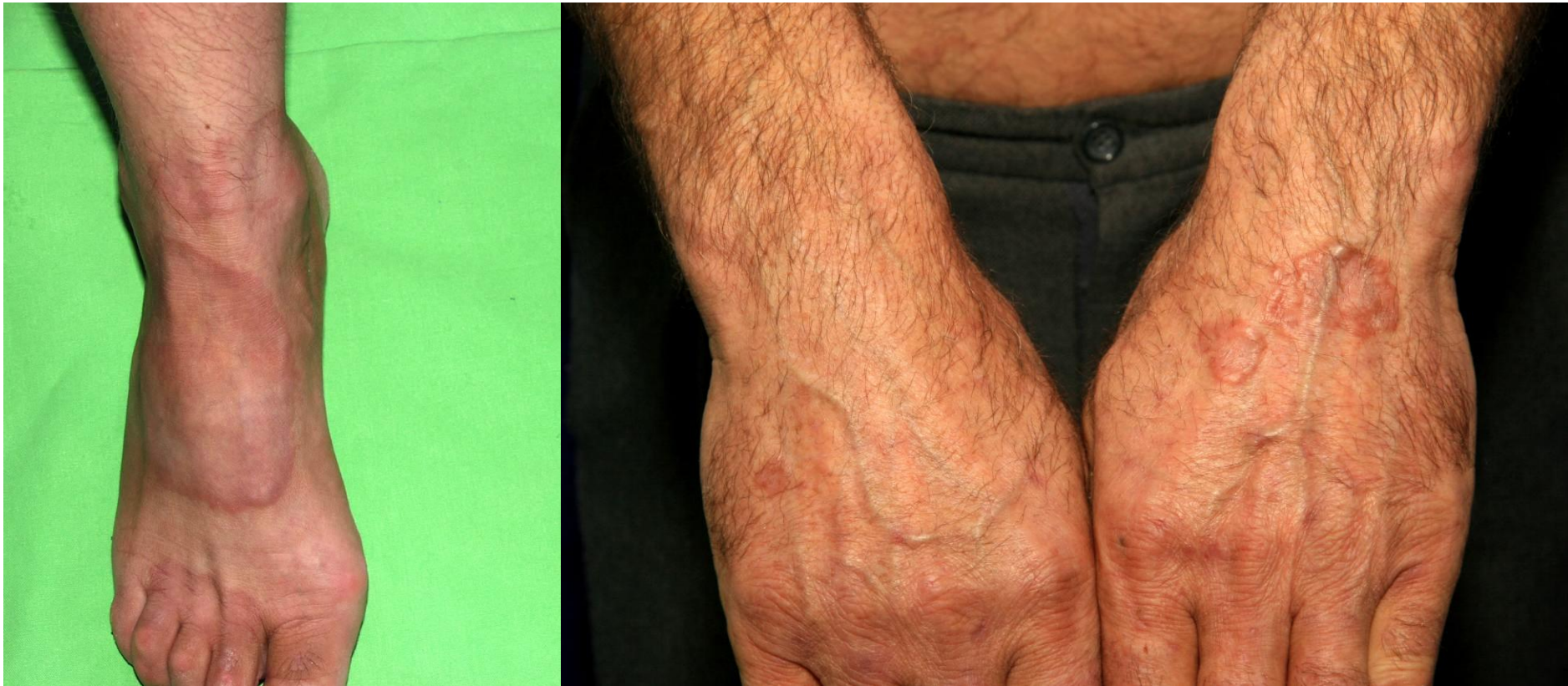Erythema Chronicum Migrans



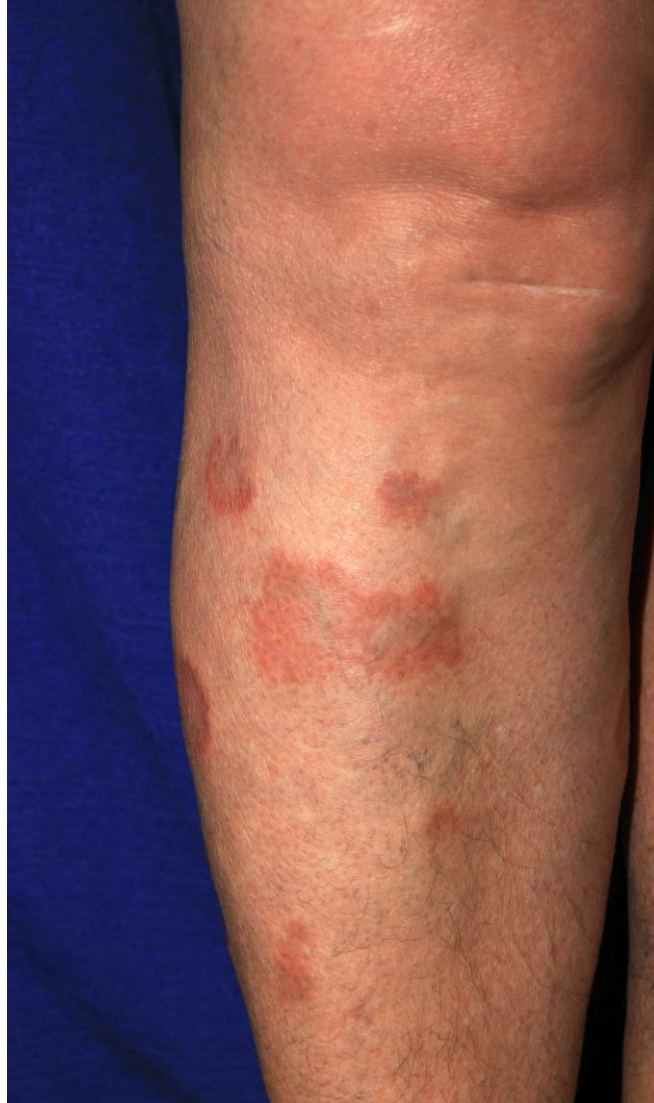Erythema Elevatum Diutinum



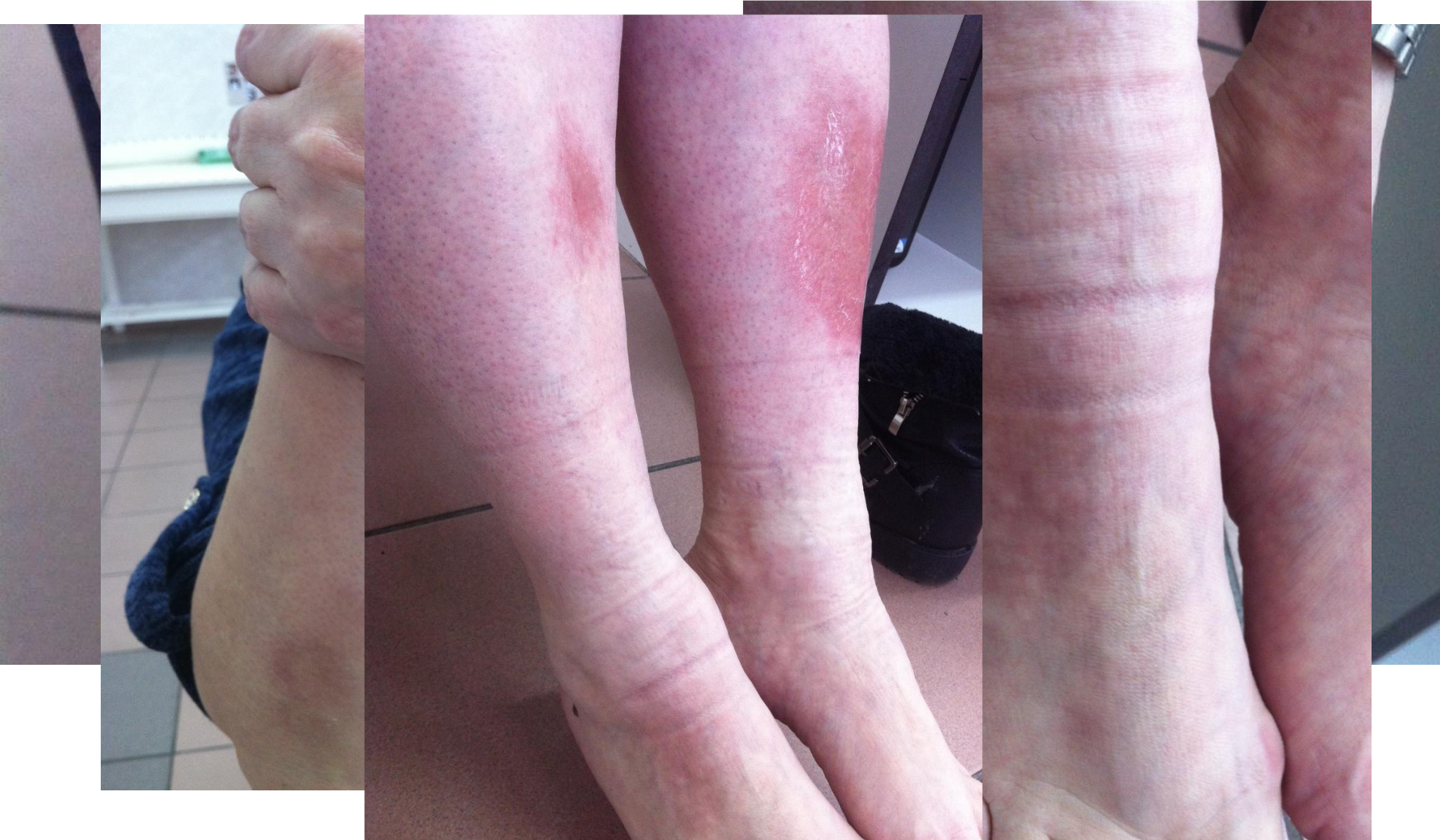“Typical” granuloma annulare (GA)



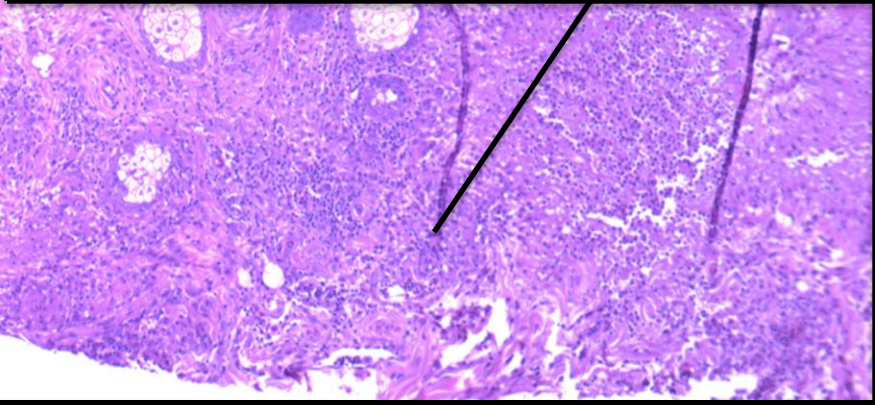
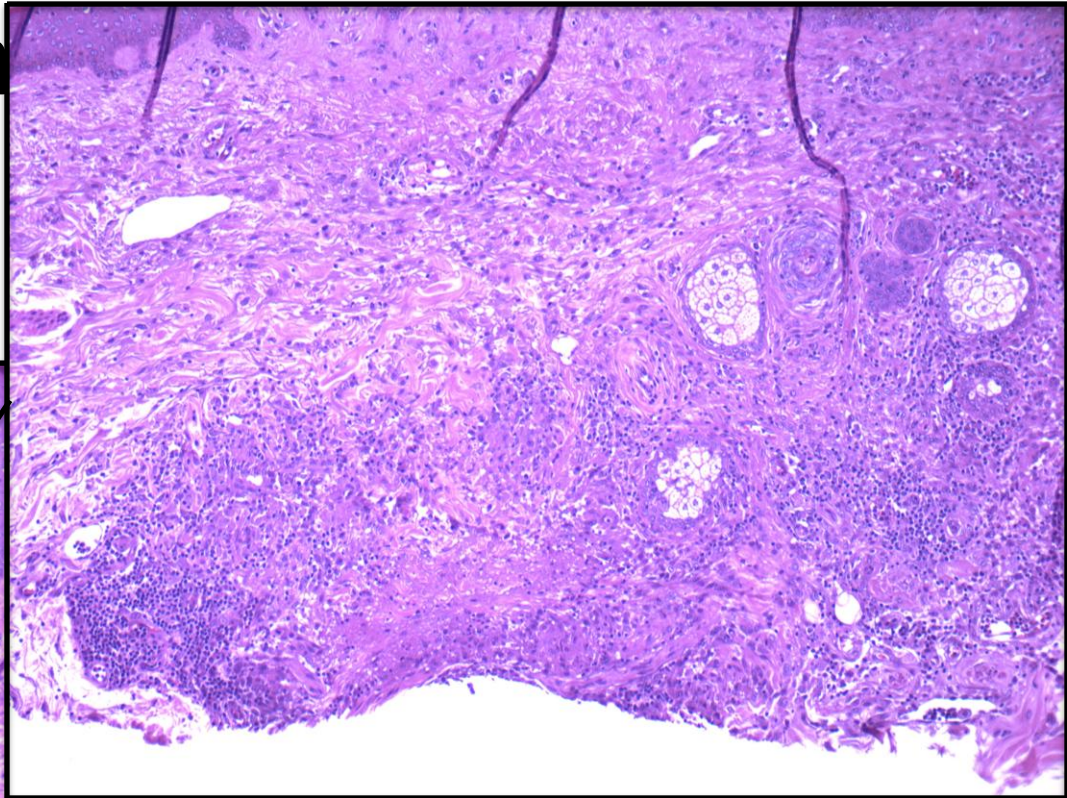
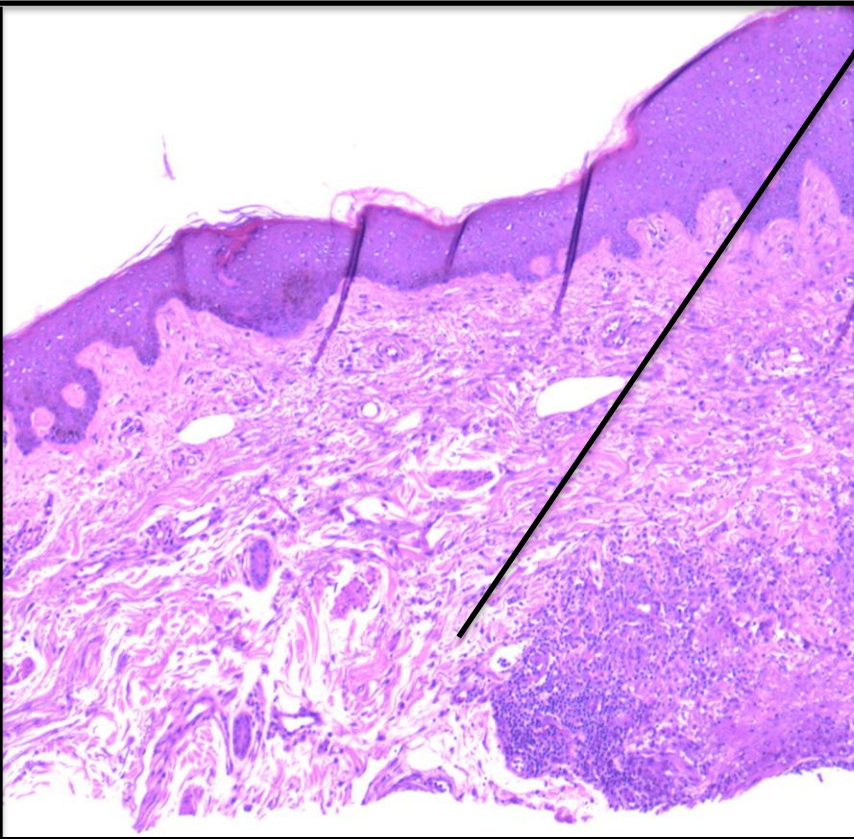
Necrobiosis Lipoidica or Granuloma annulare



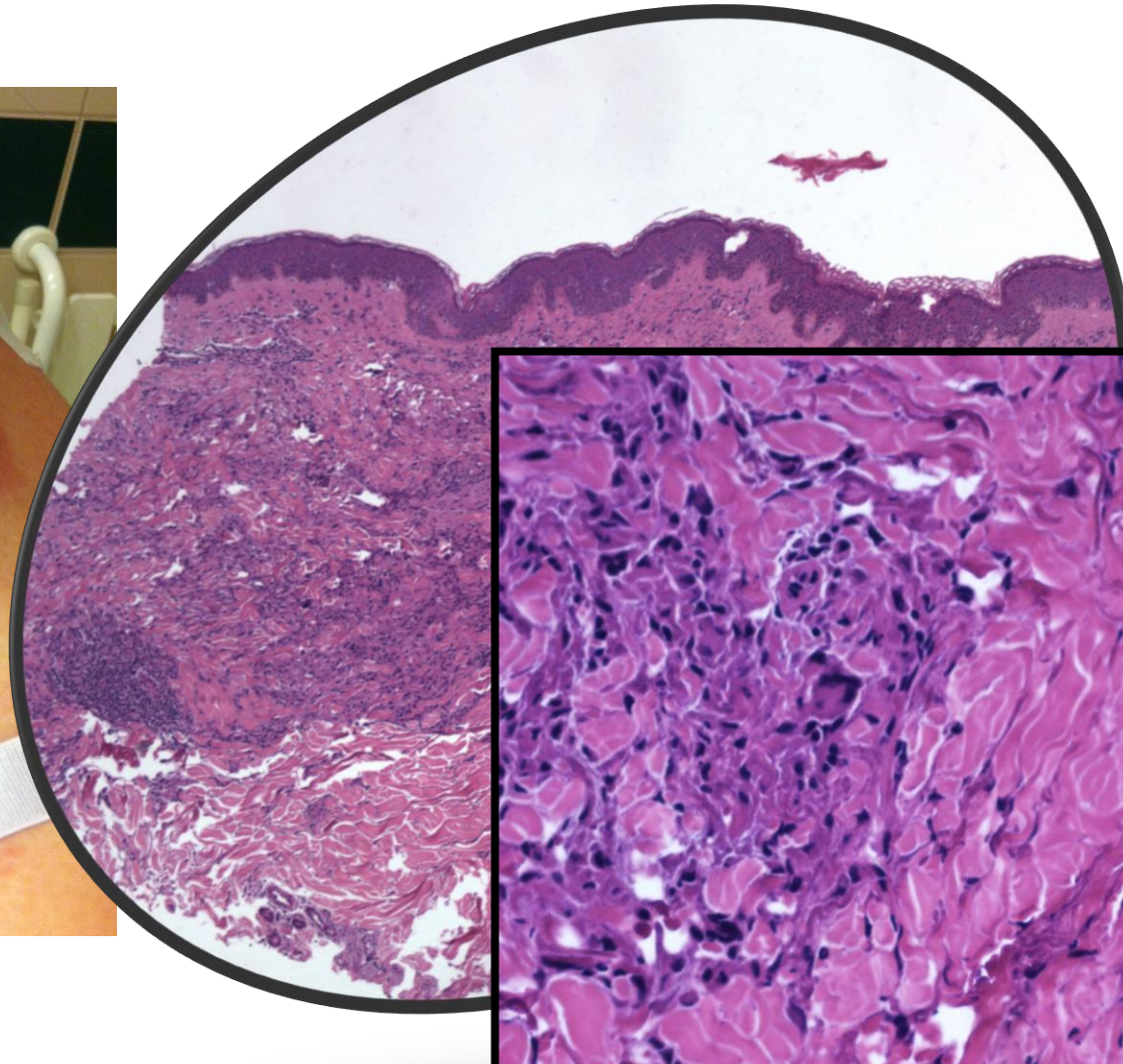
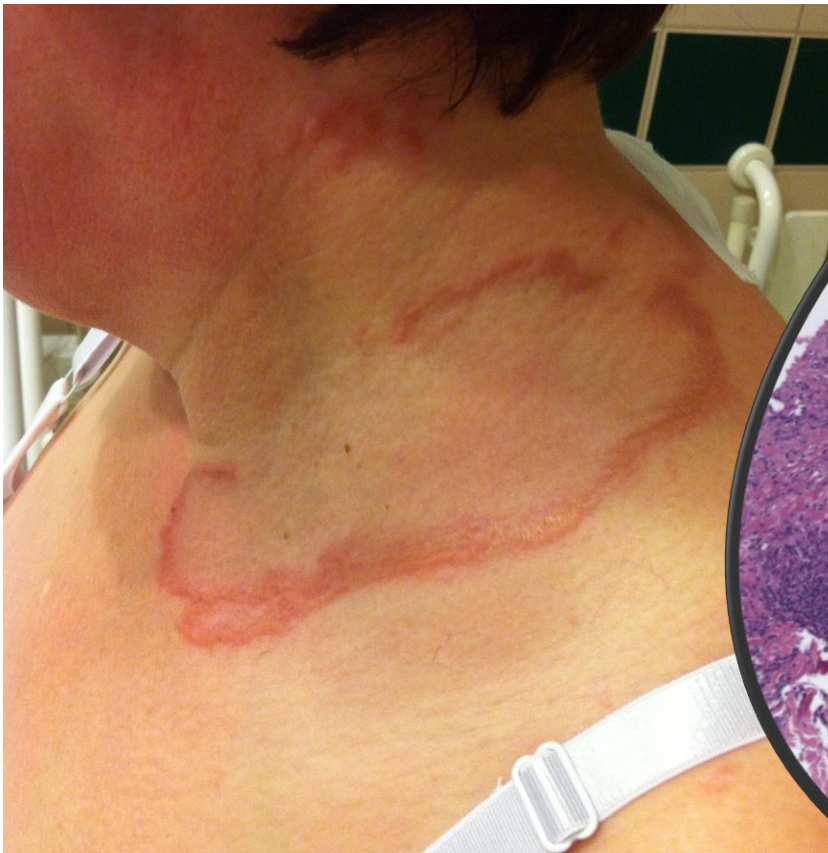Necrobiosis Lipoidica or Granuloma annulare Same Same... But different?



Granuloma ann



Annular elastolytic giant cell granuloma

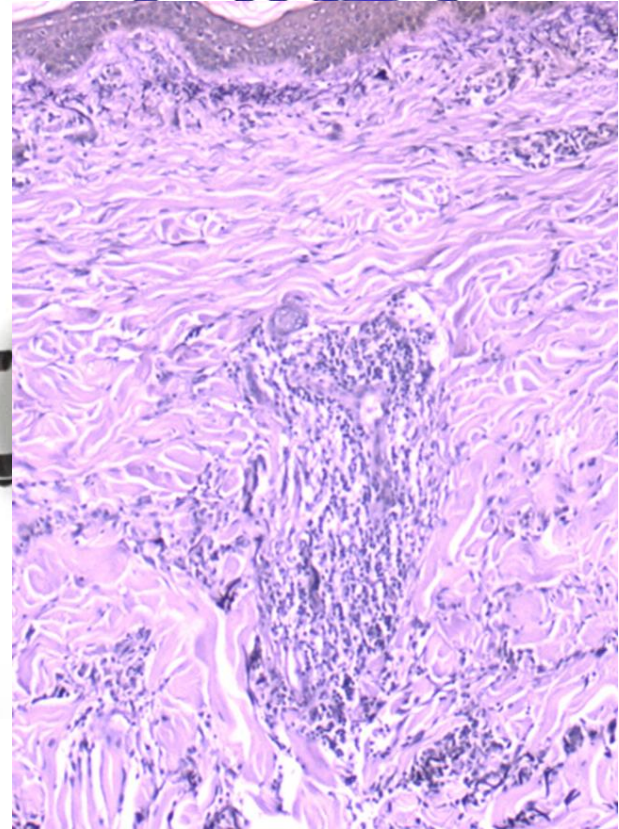




WHICH CAME FIRST



OR
THE



Patient 4

History

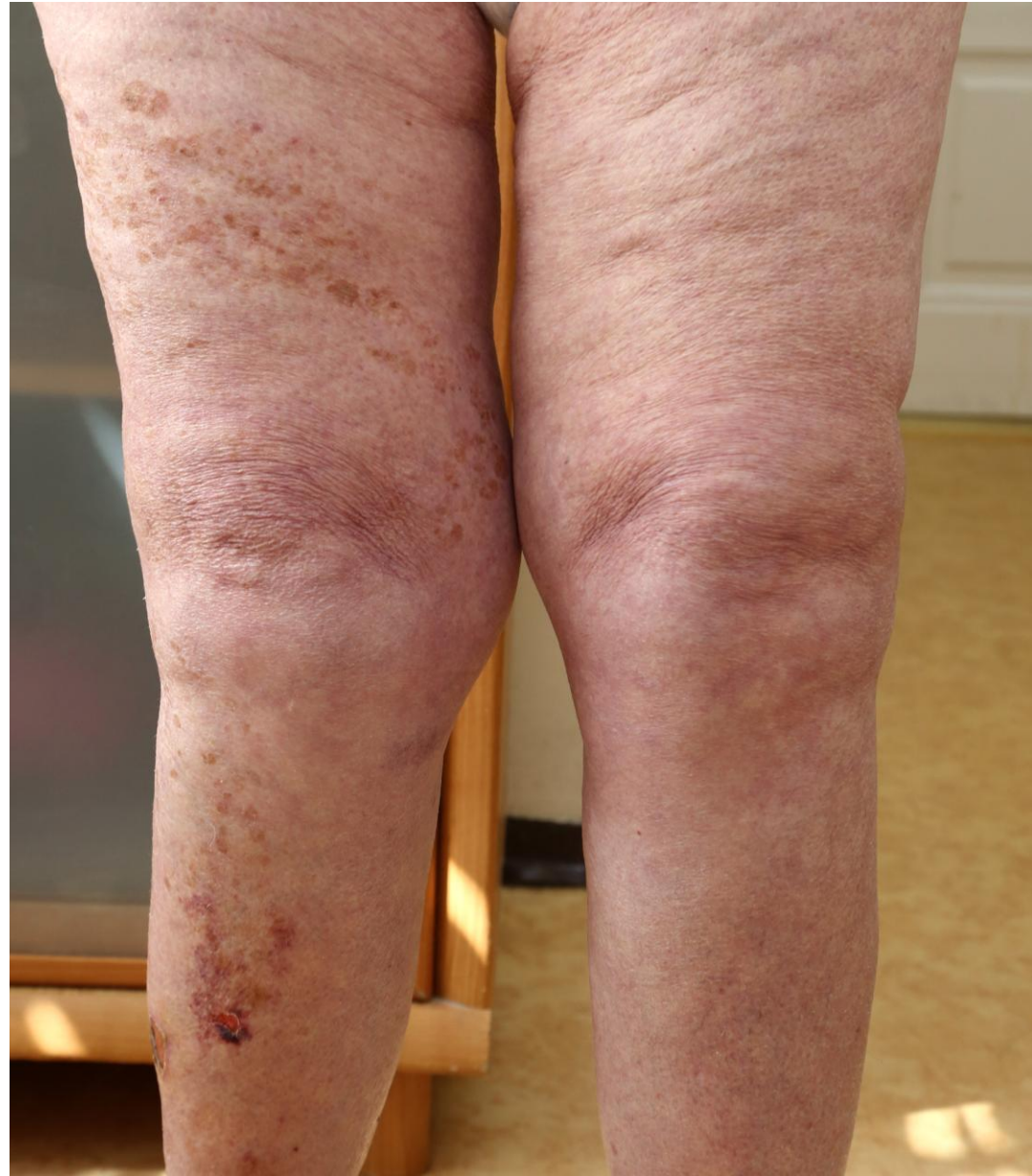- 88 y old female patient
- 65 y ago tonsillectomy
- 30 y ago vertebrobasilar insufficiency
- 25 y ago
 - hypoacusis
 - cholelithiasis
- 20 y ago
 - spondylosis (CV-CVIII)
 - oesophagus polyp
 - H. pylori positive chronic gastritis
 - Suprarenal adenoma (left side)
- 15 y ago
 - hypertension
 - gonarthrosis
- 14 y ago myasthenia gravis (receiving steroid, pyridostigmine and IVIG once)
- 13 y ago thyroid dysfunction

2015:

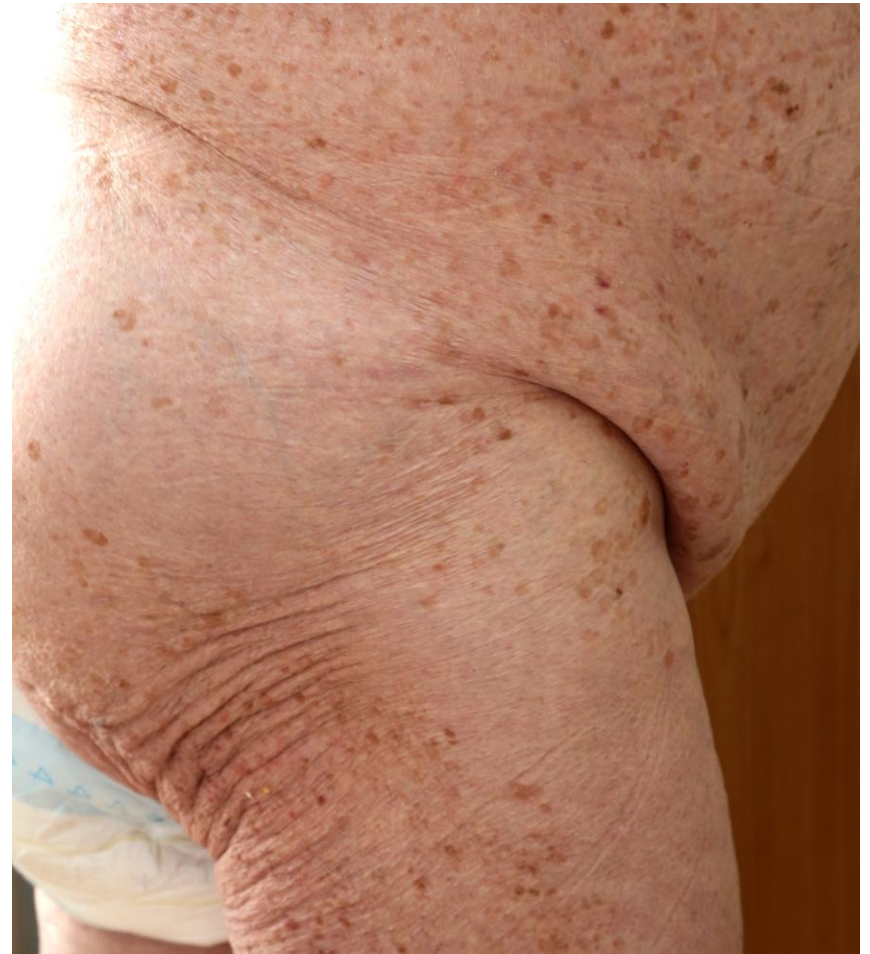
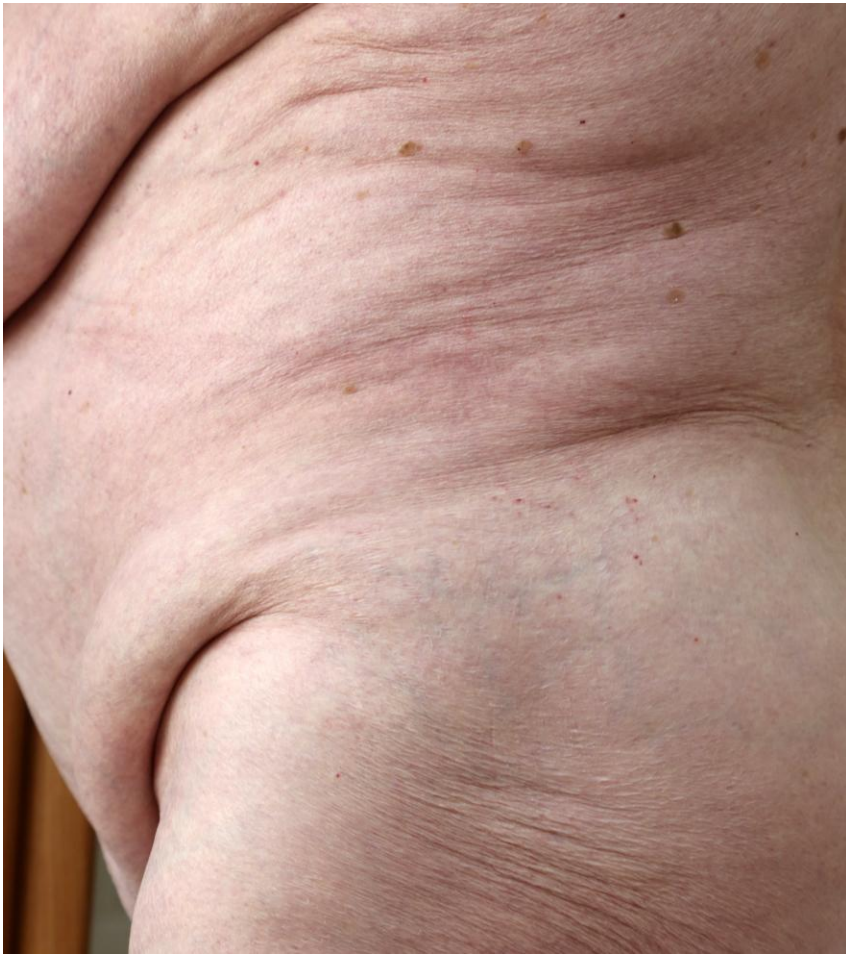Treated for *Campylobacter* infection at the Department of Infection

Consultation was asked for the scar on the right leg which was suspected to be related to the long term steroid treatment

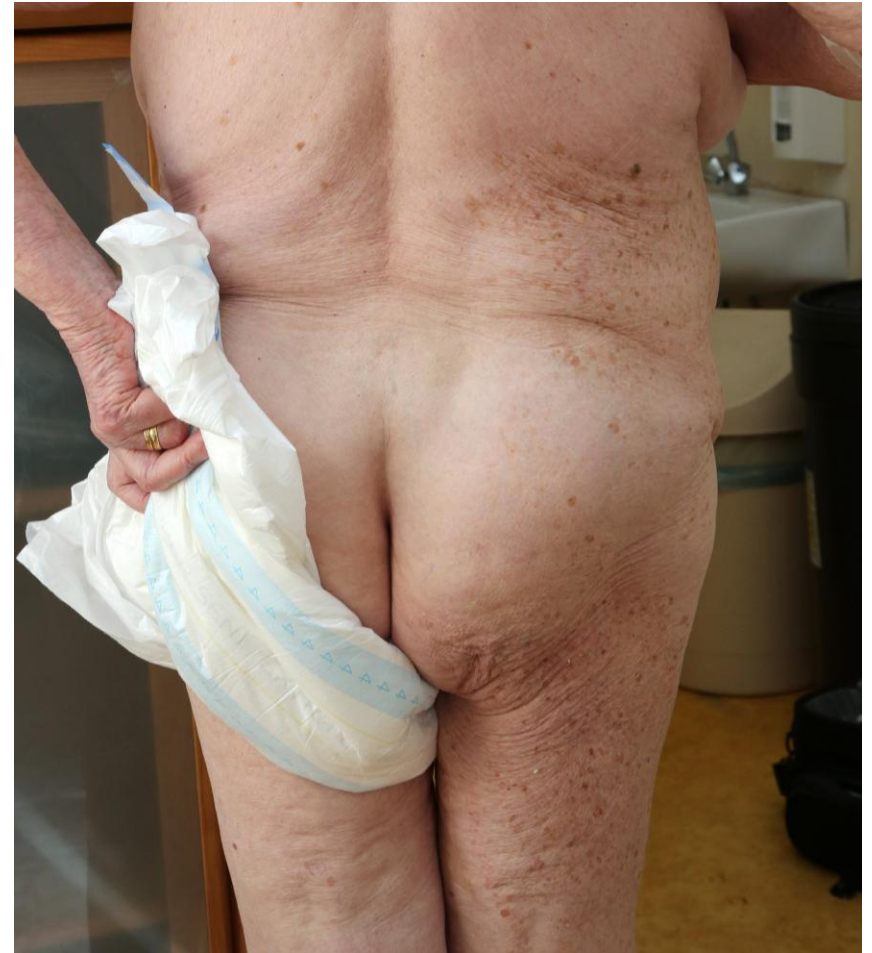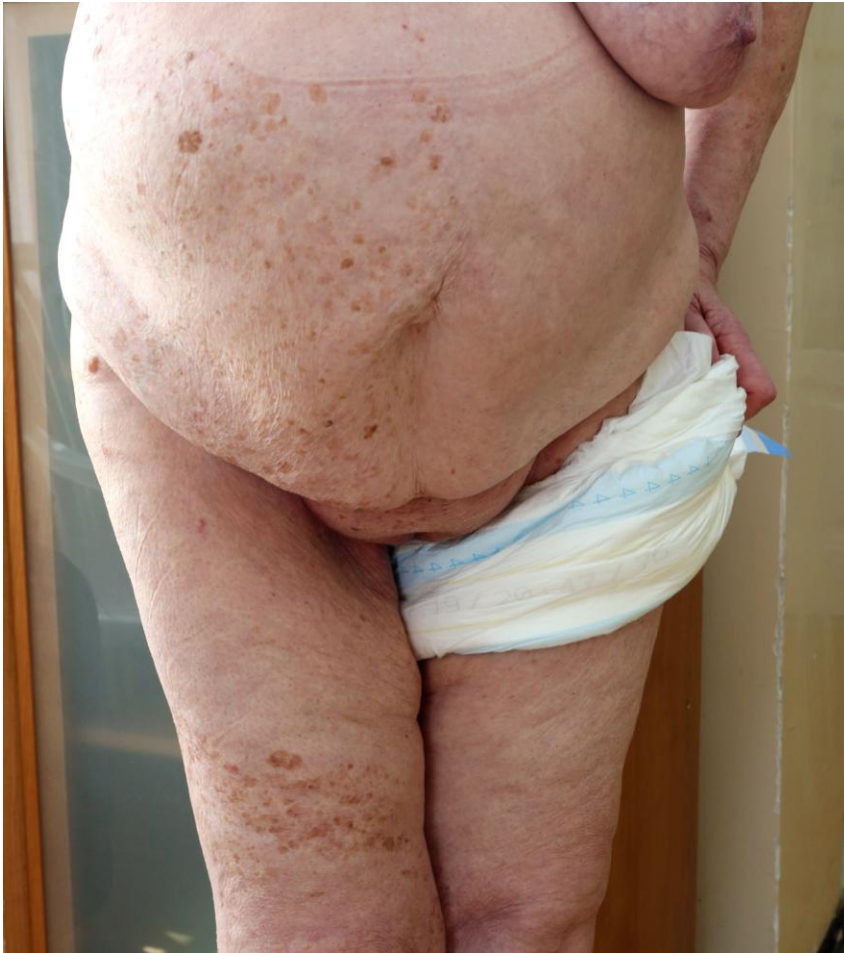At the time of examination the hyperpigmented macules were immediately noticed



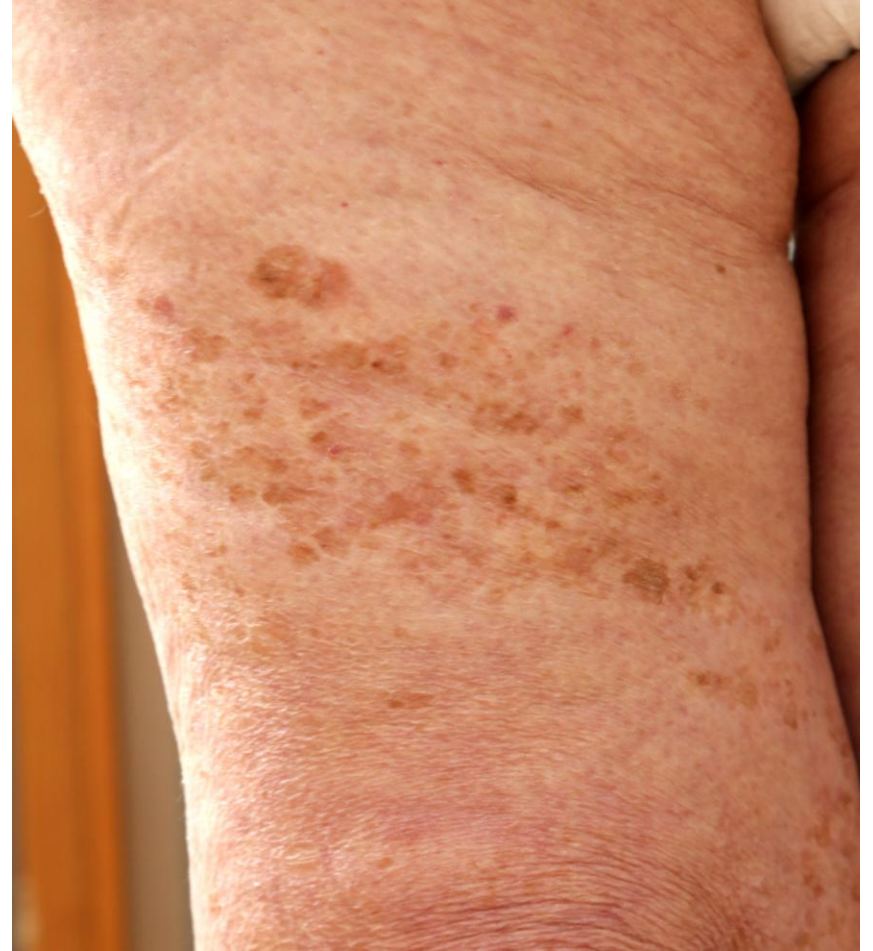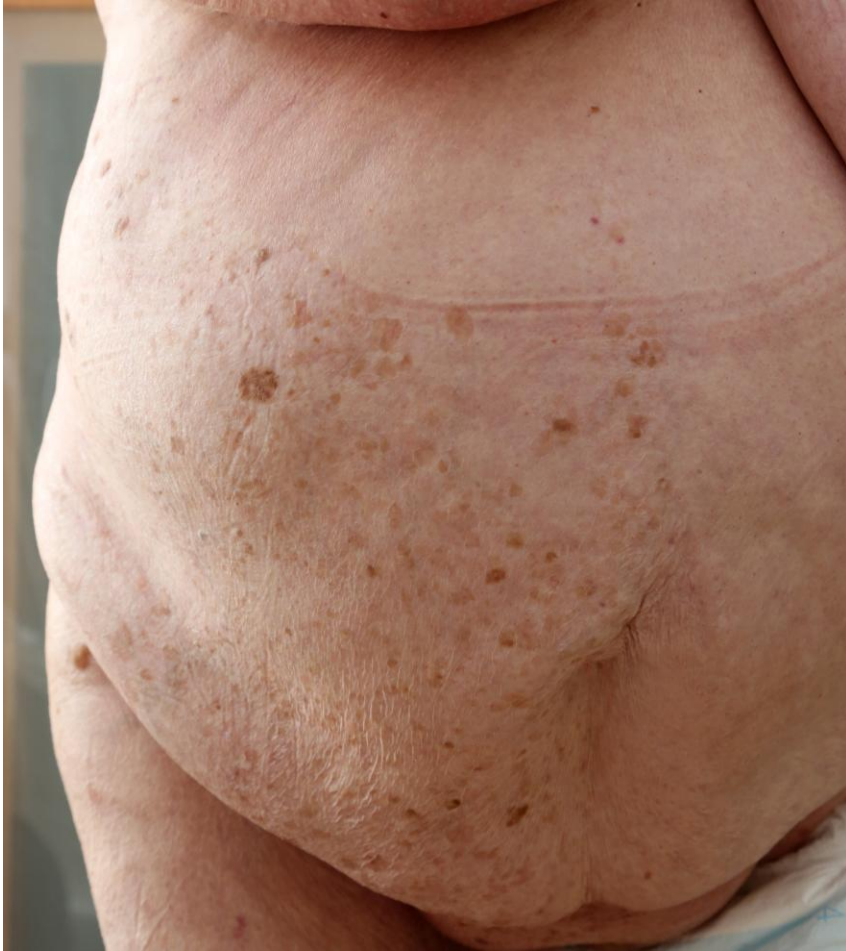The two sides of the body had
different “ages”



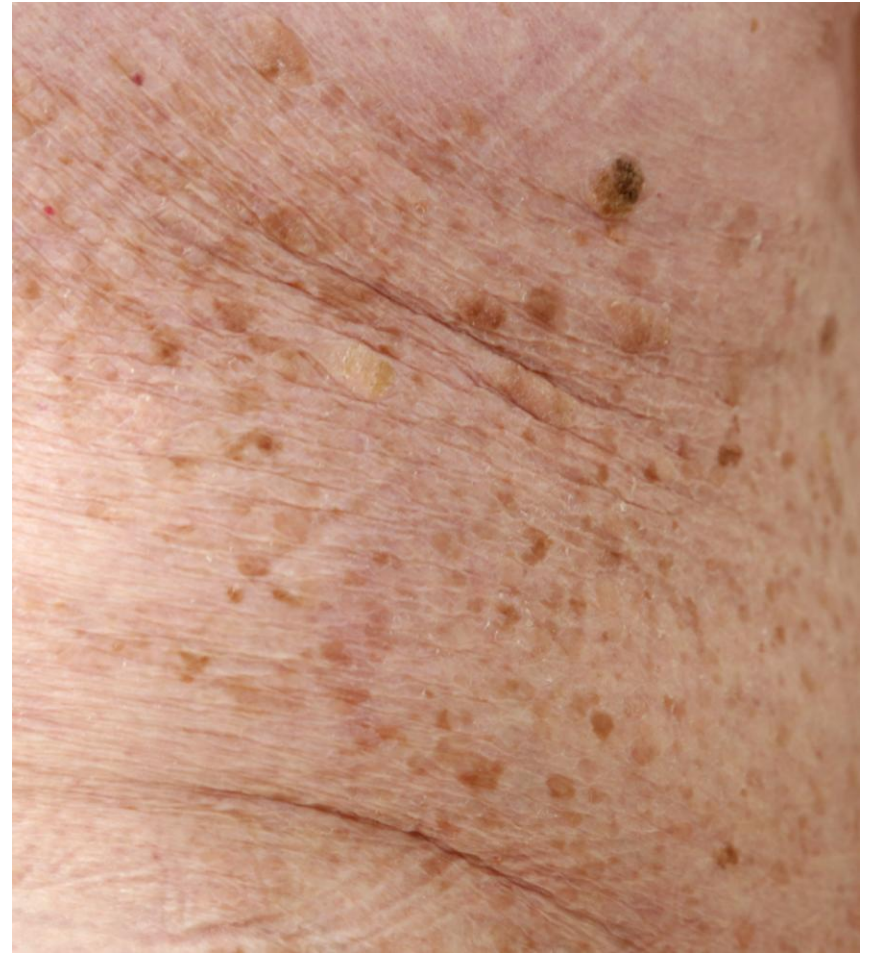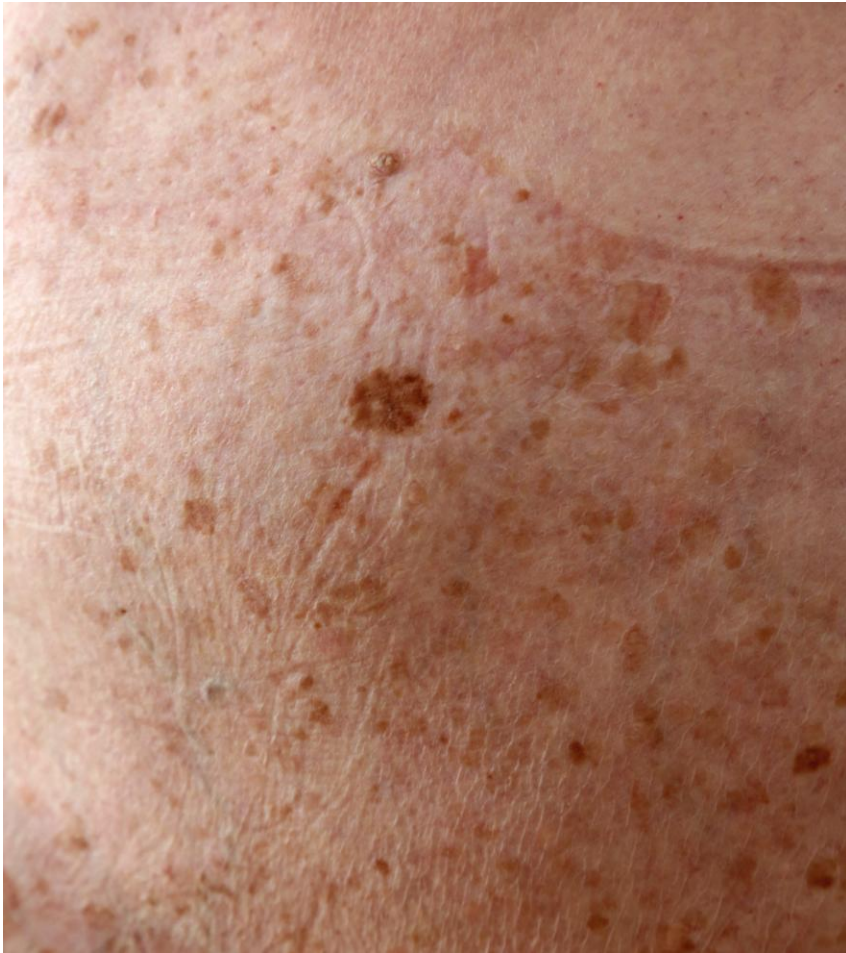“Aging” was in a dermatomal
distribution

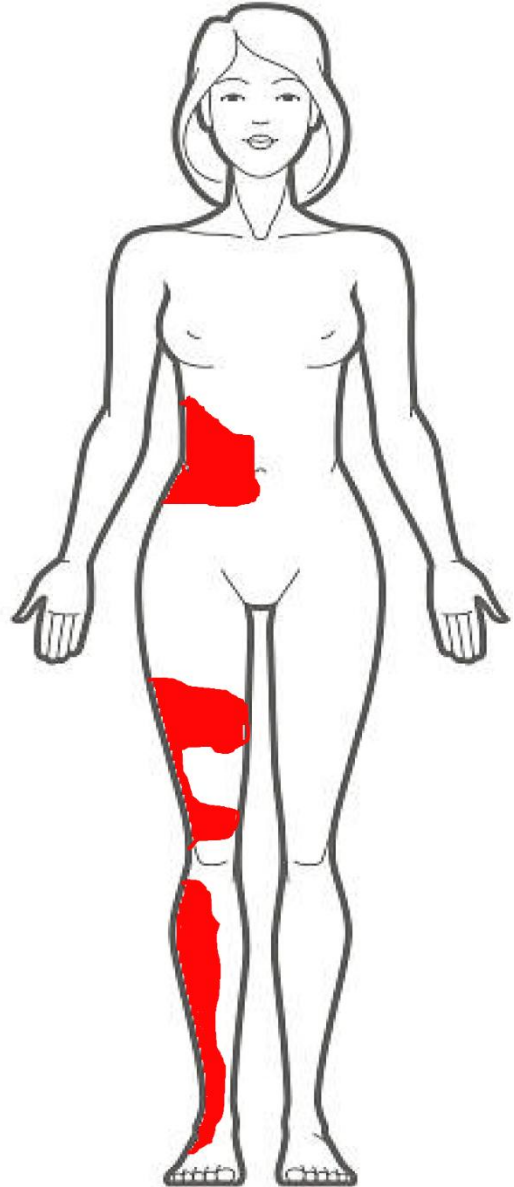
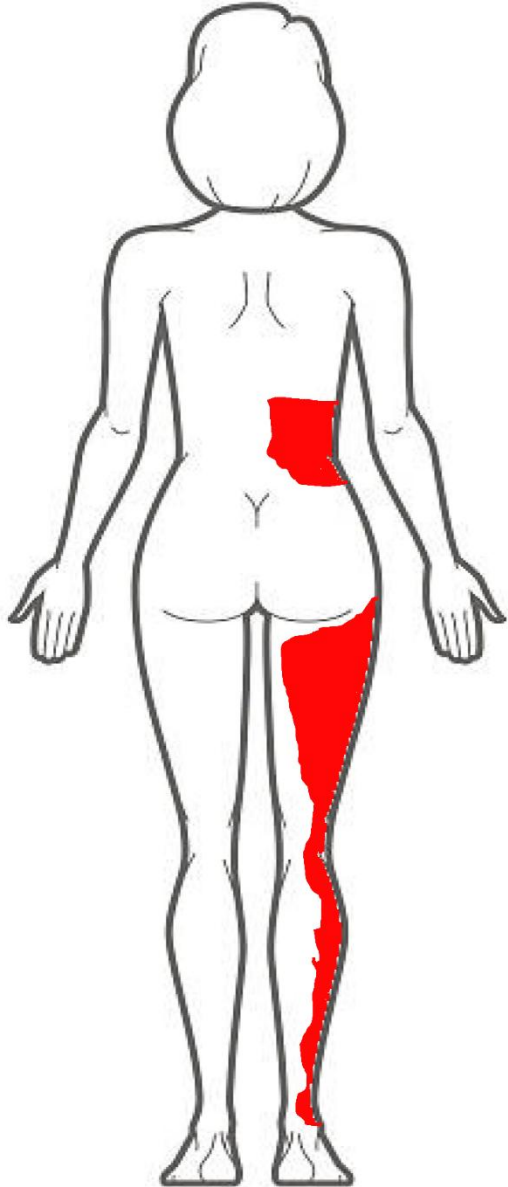
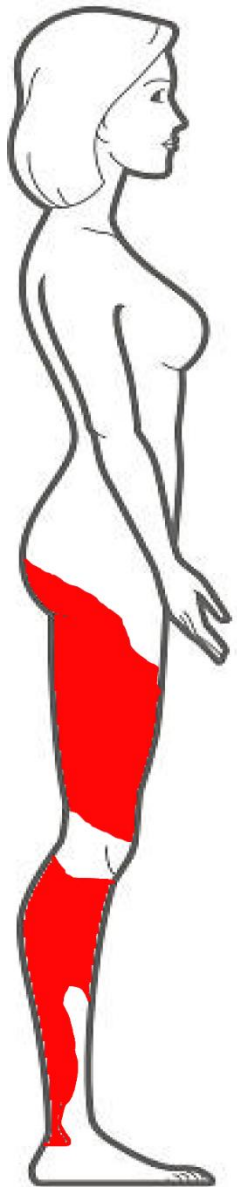


Mostly seborrheic



....and porokeratotic





2020







